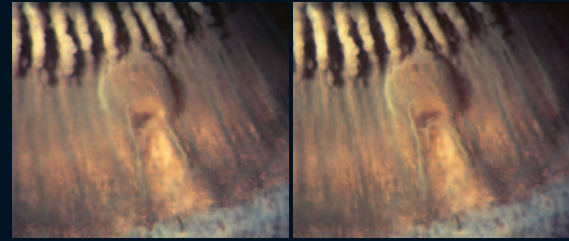
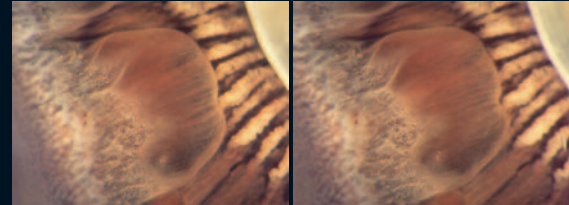


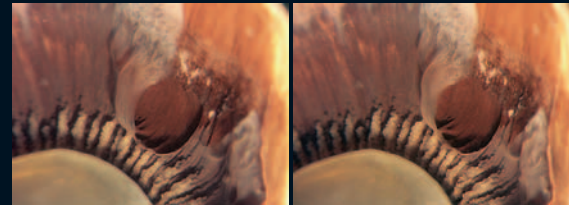
- 33 'Mushroom-shaped' pars plana cyst reaching from the ora to the pars plicata. Note the areas of cystoid degeneration.



- 34 On the temporal pars plana, there is a huge pars plana cyst with clear content, reaching the posterior end of the ciliary processes.



- 35 The pars plana is covered by huge confluent cysts with clear content, extending up to the posterior border of the pars plicata.



- 36 Large pars plana cyst with partially elevated pigment epithelium.

