

.....

Immunology of Preeclampsia

*Leif Matthiesen^a, Göran Berg^a, Jan Ernerudh^b, Christina Ekerfelt^b,
Yvonne Jonsson^b, Surendra Sharma^c*

^aDepartment of Molecular and Clinical Medicine, Division of Obstetrics and Gynaecology and ^bDepartment of Molecular and Clinical Medicine, Division of Clinical Immunology, University Hospital, Linköping, Sweden; ^cDepartment of Pediatrics and Pathology, Women and Infants Hospital of Rhode Island, Brown University, Providence, R.I., USA

Abstract

Preeclampsia is a placenta-dependent disorder with both local and systemic anomalies with neonatal and maternal morbidity. It is manifested late in pregnancy, but the onset is during early stages of gestation. The current hypothesis regarding the aetiology of preeclampsia is focused on maladaptation of immune responses and defective trophoblast invasion. Thus, an excessive maternal inflammatory response, perhaps directed against foreign fetal antigens, results in a chain of events including shallow trophoblast invasion, defective spiral artery remodelling, placental infarction and release of pro-inflammatory cytokines and placental fragments in the systemic circulation. During normal pregnancy, trophoblasts interact in the decidua with the unique uterine NK cells, modifying their cytokine repertoire, regulating adhesion molecules and matrix metalloproteinases. The inability of trophoblasts to accomplish these changes might be a critical factor for the onset of preeclampsia. Several cytokines, produced at the maternal-fetal interface, have an impact on trophoblast invasion. It is suggested that deficiency of interleukin-10 may contribute to enhanced inflammatory responses towards the trophoblasts elicited by e.g. tumour necrosis factor- α and interferon- γ . Consequently, trophoblasts subjected to a high rate of apoptosis are hampered in their invasive capacity resulting in defective transformation of spiral arteries, hypoxia, thrombosis and infarction of the placenta. The ensuing infarction of placenta leads to leakage of increasing amounts of placental fragments and cytokines in the maternal circulation and an exaggerated systemic endothelial activation as identified in preeclampsia. So far, treatment of preeclampsia is focused on signs like hypertension, whereas attempts of modifying immune responses may be a possibility in the future.

Copyright © 2005 S. Karger AG, Basel

Introduction

Preeclampsia is a complication that is detected in the second half of pregnancy, but most probably has its onset during the early stages of gestation. This

pregnancy-associated disorder is histologically characterized by restrained trophoblast invasion, vasculitis, thrombosis and ischaemia of the placenta. These features may also be apparent in other obstetric complications like recurrent spontaneous abortion, intrauterine growth retardation, fetal death, and abruptio placentae. The seemingly disparate clinical entities might have their common aetiology in the immune responses including local subclinical inflammation at the placental bed and systemically (in preeclampsia) in the maternal circulation. Preeclampsia is hard to detect in its early form and predictors that can be used to identify the women at risk of preeclampsia would be of value for the clinician. This paper deals with preeclampsia in humans and associated immunological changes and is an overview of recent important findings of this important but still poorly understood condition.

Clinical Preeclampsia

Preeclampsia occurs after the 20th week of gestation and is a heterogeneous disease. Since termination of pregnancy cures the disease, preeclampsia is a placenta-dependent disorder with both local intrauterine and systemic signs and symptoms. The hallmark signs are hypertension and proteinuria (table 1). The incidence of preeclampsia is 3–5% of all pregnancies depending on the population studied [1].

A number of risk factors are thought to increase the risk of developing preeclampsia: maternal vascular disease, autoimmune disorders, maternal and paternal genetic causes, diabetes mellitus, primiparity and twin pregnancy. Although the exact aetiology remains to be delineated, all of the associated causes converge into a common pathophysiological denominator: endothelial dysfunction. Thus, it has been suggested that an excessive maternal inflammatory response, perhaps directed against foreign fetal antigens, results in an impaired trophoblast invasion with a defective spiral artery remodelling ensued by high-resistance vessels and a reduced placental perfusion. The consequences are placental hypoxia and infarction with release of pro-inflammatory cytokines and placental fragments into the maternal circulation with ultimately generalized maternal, and possibly fetal, endothelial activation [1].

Trophoblast Invasion

An adequate trophoblast invasion is possible only after a proper endometrial decidualization of the uterine wall has occurred. The decidualization is initiated immediately after ovulation in order to receive the embryo. The production of progesterone from the corpus luteum stimulates the decidua to

Table 1. Diagnosis of preeclampsia

Definition of preeclampsia according to WHO

Preeclampsia is a syndrome defined by hypertension and proteinuria and may be associated with other signs and symptoms

Preeclampsia occurs after the 20th gestational week

Moderate preeclampsia

Systolic blood pressure ≥ 140 mm Hg and/or a diastolic pressure ≥ 90 mm Hg measured on separate occasions at least 4 h apart

Proteinuria in a 24-hour protein excretion ≥ 300 mg or 1+ on two random urine samples collected 4 h apart

Severe preeclampsia

Systolic blood pressure > 160 mm Hg and/or diastolic ≥ 110 mm Hg measured on separate occasions at least 4 h apart

Proteinuria in a 24-hour protein excretion ≥ 5 g or 3+ on two random urine samples collected 4 h apart

Cerebral dysfunction (blurred vision, scotoma, headache, cerebrovascular accidents)

Epigastric or right upper quadrant pain

Renal failure or oliguria ≤ 500 ml in 24 h

Pulmonary oedema

Impaired liver function (serum transaminase levels 2 times normal or greater)

Thrombocytopenia ($\leq 100,000$ platelets/ mm^3)

Coagulopathy

Fetal growth restriction

Eclampsia (generalized convulsions)

HELLP

increase the vascularization and secretory activity of the endometrial glands. The leukocytes in the decidua consist mainly of unique uterine natural killer (uNK) cells (65–70%) and monocyte/macrophages (15–20%), whose exact function is unknown. A small number of T cells are also present, whereas B cells are almost absent. In the endometrial extracellular matrix (consisting of different types of collagens, proteoglycans, and glycoproteins), changes occur facilitating the invasive properties of trophoblasts creating a safe anchor of the placenta in the decidua and the vascular remodelling of the spiral arteries [2, 3].

The invading cytotrophoblasts are a subpopulation of villous cytotrophoblasts, which in turn differentiate into an outer layer of multinucleated cells, the syncytiotrophoblasts. The syncytiotrophoblasts cover the fetal mesenchyme and blood vessels and are in direct contact with maternal circulating blood. Across this syncytiotrophoblast cell membrane, nutrients and oxygen are delivered to the fetus and waste products are returned to the maternal circulation.

The cytotrophoblasts that differentiate into extravillous cytotrophoblasts are designed to develop a migratory capacity to invade deep into the decidual matrix and the maternal spiral arteries. The musculoelastic media of the spiral arteries are replaced by the invading cytotrophoblasts and fibrinoid material. The spiral arteries are thereby modulated into low-resistance flow channels allowing increased blood volume to the intervillous space [3]. The invasion of cytotrophoblasts relies on their expression of cell adhesion molecules and secretion of proteolytic enzymes, matrix metalloproteinases (MMP). Integrins are cell membrane adhesion receptors that adhere to different matrix glycoproteins depending on their expression of tissue-specific $\alpha\beta$ subunits. When trophoblasts migrate across the basement membrane and into the decidua towards the spiral arteries their expression of integrins is modulated according to the structure of the surrounding tissue. The surrounding matrix is digested by proteolytic enzymes secreted by the trophoblasts. Thus, the integrins and proteases together give trophoblasts a migratory capacity, which is a significant physiological adaptation for a successful pregnancy outcome. A shallow trophoblast invasion results in a poor placenta vascularization and deficient anchor in the matrix tissue. This is associated with a high risk of preeclampsia, intrauterine growth retardation and abruptio placentae [3–5].

Balancing Act between Inflammatory and Anti-Inflammatory Immune Responses

The trophoblast invasion is under the influence of several cytokines produced at the maternal-fetal interface by several cells of immune and non-immune origin, such as leucocytes including NK cells, trophoblasts, stromal cells and glandular endothelium [6]. Thus, the current hypothesis regarding the aetiology of preeclampsia should focus on maladaptation of immune responses and defective trophoblast invasion (fig. 1). The activation of the adaptive immune response is characterized according to the phenomenon of polarized cytokine secretion by T helper (Th) cells. These are primarily divided into two subsets: Th1 and Th2. In humans, Th1 cells secrete inflammatory cytokines such as interferon- γ (IFN- γ) and tumour necrosis factor- α (TNF- α), whereas Th2 cells secrete anti-inflammatory cytokines such as IL-4, IL-5, and IL-9. Both Th1 and Th2 cells as well as non-lymphoid cells, including macrophages, secrete IL-10. Although the Th1/Th2 model is too simple to encompass all the complex differentiation profiles of cytokine-producing cells, it still provides a useful framework to explain the immune responses imparted either by immune cells or non-immune cells [7].

An important decisive factor for the induction of either the Th1 or Th2 pathway is the presence of certain cytokines during the initial process when

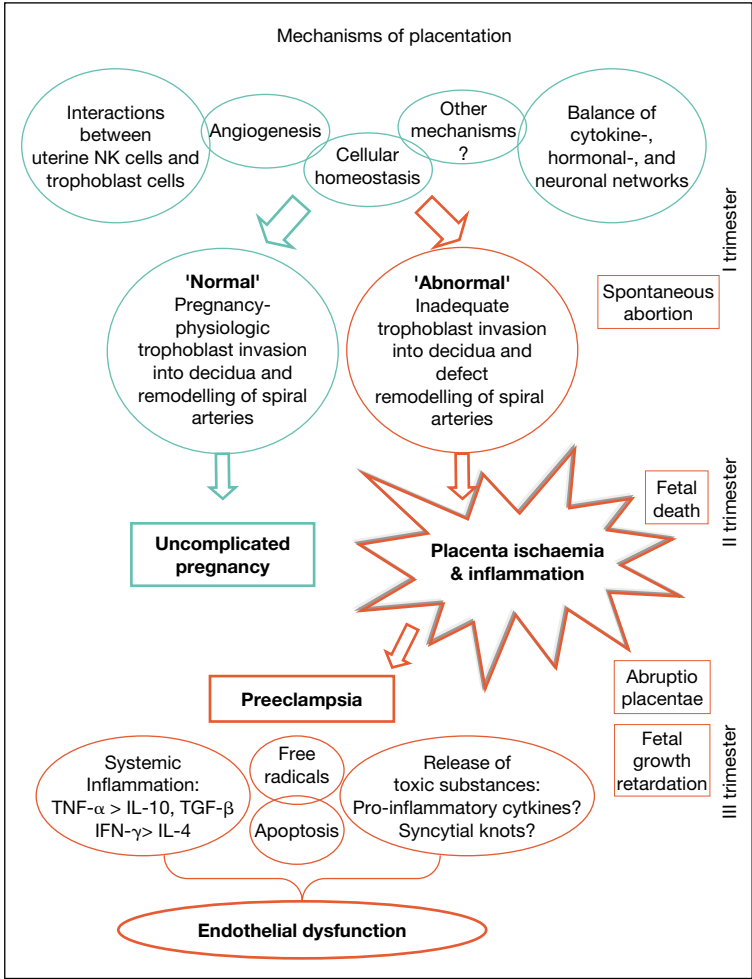


Fig. 1. Flow chart showing mechanisms of placental development in uncomplicated pregnancies ('normal') and of pathological placentation ('abnormal'), as in preeclampsia. Other pregnancy complications, spontaneous abortion, fetal death and growth retardation, may also be clinical signs of placental ischaemia and inflammation as shown.

antigens are recognized. IL-4 dictates the immune response to Th2 and the effects of IL-4 have been shown to dominate over those of IFN- γ [8]. Thus, it is possible that the presence of the trophoblasts in a uterine cavity with a poor resident anti-inflammatory milieu initiates an incompatible activation of the decidual immune cells that direct the local immune activity towards inflammation.

Subsequently, the systemic cytokine production and immune responses are likely to be predominant in their inflammatory functions which might initiate the pathology associated with preeclampsia.

Cytokines and Preeclampsia

A set of cytokines have so far been of particular interest in the pathological pregnancy outcome, including preeclampsia (fig. 1).

Transforming Growth Factor- β

Transforming growth factor- β (TGF- β) is secreted by decidual stroma cells, macrophages and T cells and is present locally at the maternal-fetal interface. This cytokine exerts a regulatory role by a potent negative effect on trophoblast invasiveness by induction of tissue inhibitors of matrix proteases and increased adhesiveness to matrix proteins [5, 6]. However, the impact of an overexpression of TGF- β on a shallow cytotrophoblast invasion at the fetal-placental unit has been disputed since no difference was found either in the placental bed or in the placenta in preeclamptic patients compared with normal pregnancies [9].

Tumour Necrosis Factor- α

TNF- α is a proinflammatory cytokine produced e.g. by NK cells, monocytes/macrophages and trophoblasts. TNF- α promotes apoptosis and leakage of the endothelial vessels, leading to systemic endothelial activation and thereby signs associated with preeclampsia [10]. In conjunction with an overexpression and secretion of TNF- α in the placenta and in plasma – as observed in preeclampsia – an enhanced plasma and placental expression of IL-1 has been reported. IL-1 and TNF- α both promote structural and functional changes in endothelial cells including oxidative stress, activation of the complement cascade, secretion of vasoconstrictors, microthrombosis and infarction, and elevated thromboxane levels. All these changes are seen in preeclampsia and the effects of increased expression of TNF- α seem to be involved in the pathophysiological mechanisms leading to the clinical signs [1, 11]. Thus, TNF- α is a major contributor to many of the local and systemic changes that characterize preeclampsia. TNF- α has also been shown to elevate leptin protein levels, a phenomenon associated with preeclampsia. Interestingly, microarray analysis of differentially expressed genes in placental tissue of preeclampsia revealed that one of the most upregulated transcripts in preeclampsia tissue was the obese leptin gene [12].

Interferon- γ

IFN- γ released by activated T cells activates the specialized uNK cells which possess regulatory properties for physiological trophoblast invasion in the decidua. However, excessive amounts of IFN- γ in conjunction with TNF- α and IL-1 can lead to apoptosis of trophoblasts [2, 13]. This may indeed also be the case in unexplained spontaneous abortions [14]. In an inflammatory environment, macrophages secrete high levels of IL-12 that stimulate IFN- γ secretion by NK cells, thereby inhibiting angiogenesis [6].

IL-10

IL-10 is an important anti-inflammatory cytokine in pregnancy that inhibits upregulation of MMP-2 and MMP-9 and promotes the termination of Th1 inflammatory rejection reactions against the fetal-placental unit. In a small number of preeclampsia cases, high levels of IL-10 are seen both in the placenta and in peripheral blood, which might be a compensatory response to elevated levels of IFN- γ , TNF- α , IL-2 and IL-12 [5, 8, 15]. On the other hand, IL-10 deficiency and an increase of TNF- α expression in the placenta and decidua are observed in preeclampsia compared to those with a normal pregnancy. This was interpreted as a modified immune balance consistent with inflammatory responses in preeclampsia [16]. This suggests that coupling of IL-10 deficiency and inflammatory signals at different stages of pregnancy may contribute to disparate clinical conditions, including preeclampsia [17, Sharma, unpubl. observations].

Other Cytokines

Recently, several other cytokines have been identified in the immunopathological cascade of preeclampsia. Since these cytokines do not adjust to the original concept of Th2 as beneficial and Th1 as deleterious to pregnancy, it has been proposed that caution should be observed with the immunotrophism theory stated by Wegmann et al. [18]. Nevertheless, the Th1/Th2 paradigm in its simplistic form may still be part of complex immune-endocrine interactions locally or systemically. In this context, Chaouat et al. [19] suggest that the preclinical cytokine network has come closer to the patient bedside, showing a correlation between the evaluation of uterine blood flow, ultrasonographic morphology of uterine-placental vessels and immunohistochemical localization and levels of IL-12, IL-18 and counts of uNK cells. They showed, in a group of patients enrolled in an in vitro fertilization programme, that a correlation exists between cytotoxic cytokine profiles and vascular anomalies in implantation failures. This scenario is in contrast with the proper activation and localization of uNK cells and vasculature seen in implantation success. Pro-inflammatory cytokines trigger

activation of the coagulation cascade leading to vasculitis and infarction and may further deteriorate the early placental development and hamper the trophoblast invasion [1, 5, 10].

Recently, an elegant way of measuring cytotoxic responses, by means of granulysin levels in serum, was reported to be associated with the occurrence and clinical manifestations of preeclampsia [20]. The real challenge is to find early markers of subsequent preeclampsia. In this context, soluble IL-2 receptor in plasma was elevated in the 1st trimester of women that later developed preeclampsia compared with controls [21].

Maternal-Fetal Interactions

In the uterine cavity, the extravillous cytotrophoblast cells reveal themselves by the expression of the unusual HLA class I molecules: HLA-E, and HLA-G together with HLA-C. At present, the only receptors that have been found to these HLA class I molecules are located on the unique uNK cells (fig. 1). uNK cells are CD56^{bright} CD16⁻ compatible with a low cytotoxic potential compared with the classical killer NK cells in peripheral blood that express CD56^{dim} CD16⁺. The syncytiotrophoblast, covering the placental villi and thereby exposed to maternal blood, expresses no HLA molecules [2].

The uNK cells show a variation over the menstrual period. During the luteal phase and until midgestation uNK cells increase in number and they accumulate around the invading cytotrophoblasts. After initial development of the placenta, levels of uNK cells decline and cease to be present at term [2].

The interaction between extravillous cytotrophoblasts and uNK cells, possibly after stimulation by IFN- γ , has recently been suggested to have an influence on the remodelling of spiral arteries [22]. A high expression of receptors signalling inhibition of cytotoxic activity of uNK cells interacts with HLA-E, HLA-C, and HLA-G [2].

The inability of cytotrophoblasts to modify the cytokine repertoire of uNK cells and their regulation of adhesion molecules, MMPs and sufficient neovascularization may be critical factors for the onset of pregnancy complications including preeclampsia [2, 3, 6, 17, 18].

Apoptosis and Syncytial Knots

Programmed cell death or apoptosis plays an important role in cell homeostasis and tissue remodelling, particularly placental development. Importantly, placental degeneration observed in preeclampsia may be due to unscheduled

apoptosis of trophoblasts. The pregnancy-associated remodelling of the spiral arteries is mediated by invasive cytotrophoblasts. However, if these trophoblasts are subjected to a high rate of apoptosis, this defective transformation of spiral arteries may result in local ischaemia, thrombosis and infarction (fig. 1). The exact causes of enhanced apoptosis in preeclampsia are currently unknown. Likewise, increased apoptosis of syncytiotrophoblasts may increase the amount of syncytiotrophoblast debris, syncytial knots, that leak into the maternal circulation and generate an exaggerated systemic endothelial activation [23]. Sargent et al. [24] have proposed that when syncytial knots break off in increasing amounts from the placenta and are shed into the maternal circulation they may be the cause of the systemic endothelial activation that is seen in preeclampsia (fig. 1). The deported trophoblast debris can, in vitro, activate maternal sources of TNF- α and IL-12 from monocytes, which further pushes the systemic immune response towards extensive inflammation instead of the normal innate immune reactivity that syncytial knots usually accomplish during pregnancy. The reason for this strong apoptosis is unknown, but it has been shown that pro-inflammatory cytokines are capable of upregulating Fas/FasL genes, while anti-inflammatory cytokines protect trophoblasts against Fas-induced apoptosis [24, Sharma, unpubl. observations].

Free Radicals

Other mediators of inflammation are also important in the pathogenesis of preeclampsia, including reactive oxygen species, in particular superoxide anions. These agents are increased in preeclampsia, where the equilibrium of antioxidants (vitamin E, ascorbic acid, glutathione peroxidase, superoxide catalase/mutase, and caeruloplasmin) is disturbed. Antioxidants are produced by many cells, also trophoblasts and leucocytes, to protect them from free radicals or as part of cellular homeostasis and ageing. Free radicals and levels of lipid peroxidation are increased in preeclampsia and capable of evoking systemic endothelial activation, including platelet consumption, altered thromboxane/prostacyclin ratio, increased TNF- α production and promotion of the coagulation cascade [25].

During normal pregnancy, a rise in antioxidants is detected in blood with increasing gestational age. However, if the inflammation is strong or the production of the antioxidants is low, the predominating condition inevitably favours oxidizing species. This is the case in preeclampsia, where free radicals are present at significantly higher levels than during normal pregnancy [25] (fig. 1). In the 'haemolysis, elevated liver enzymes, low platelet' (HELLP) syndrome, haemolysis of erythrocytes might occur due to a high degree of oxidation of glutathione,

which causes cell damage. As a consequence, it has been suggested that treatment with inhibitors of cyclooxygenase to block oxidative stress on erythrocytes as well as nutritional supplements with antioxidants, vitamin E and C, might reduce the incidence of preeclampsia in high-risk pregnancies [25].

Lymphocyte Populations in Blood

Preeclampsia is also characterized by systemic changes in the distribution of lymphocyte populations in peripheral blood. Increased levels of activated/memory cells (CD4+CD45RO+ and CD4+CD29+) and decreased levels of naïve/‘suppressor’ cells (CD4+CD45RA+) have been noted. The interpretation is that antigens have activated the T cells observed in preeclampsia. In contrast, lymphocytes in normal pregnancy are switched towards a predominance of CD4+CD45RA+ naïve/‘suppressor’ T cells. The level of cytotoxic CD8+ T cells expressing the S6F1 marker, which represent killer effector functions, is increased in preeclamptic pregnancies compared with normal pregnancies, again indicating inflammatory activity [26].

The mechanisms behind leucocyte activation in preeclampsia are unknown, but the changes are similar to those observed in humans after viral or bacterial infections. Low doses of bacterial endotoxin injected into pregnant rats resulted in a condition resembling preeclampsia including the appearance of T cell activation markers [15]. This presents an intriguing basis to probe the role of clinical and subclinical infections in the pathogenesis of preeclampsia. These observations also indicate that preeclampsia is associated with both the innate and the adaptive immune activity in the peripheral blood [6, 18, 24, 26].

Toxic Substances of Preeclampsia

What is the nature of the ‘toxic’ substances that escape from an obvious ‘sick’ placenta, swim out into the maternal circulation and gain access to and disturb almost every organ in the human body and reveal their presence by the characteristic signs and symptoms of preeclampsia (fig. 1)? Many candidates (fig. 1) have been suggested although no complete agreement has been reached [1, 6, 10, 11, 16, 18, 23–25].

Concerning cytokines as potential villains and as potential diagnostic tools in the prediction of preeclampsia, we addressed this question (like many others) by measuring cytokine levels in serum using the Luminex[®] assay (Camarillo, Calif., USA) in preeclamptic patients (n = 15) and compared them with normal

pregnancies (n = 15). In preeclampsia, we observed an upregulated systemic innate immune reactivity with increased levels of TNF- α , IL-6, and IL-8. When we stimulated peripheral blood mononuclear cells with paternal antigens ('fetus-specific') or recall antigens (purified protein derivatives of *Mycobacterium tuberculosis* or tetanus toxoid) similar levels of induced secretions of IL-4, IL-10, IL-12 and IFN- γ (detected by the highly sensitive ELISPOT assay) were detected in preeclampsia and normal pregnancies. This does not exclude local cytokine aberrations at the placental level that are compatible with inflammatory activity. However, the results agree with the main concept of preeclampsia being an inflammatory phenomenon [1, 6, 15, 18, 23, 24], but with a much more complex picture than a Th1 deviation only [19].

Conclusion

Preeclampsia is a multisystem disorder based on a cascade of immunopathological events originating from the placenta. No single candidate mechanism exists to explain the complex pathogenesis. As of now, there is no reliable marker or predictor of preeclampsia. Clearly, however, local as well as systemic inflammatory activity occurs in preeclamptic patients. To identify these complex immune factors and 'arrange' them in a test where the diverted inflammatory activity will be detected should be the target in future research concerning preeclampsia.

To further elucidate the mechanisms underlying preeclampsia, it is our hope that animal models can be developed in the very near future, wherein depletion or the overwhelming presence of key players in the aetiology of the disease can be studied developmentally.

Acknowledgment

This study was supported by the US Public Health COBRE grant 1 P20 RR018728 (SS) NIH, a grant of the County Council of Östergötland, Sweden and a grant of the Health Research Council in the South-East of Sweden.

References

- 1 Roberts JM, Taylor RN, Musci TJ, Rodgers GM, Hubel CA, McLaughlin MK: Preeclampsia: An endothelial cell disorder. *Am J Obstet Gynecol* 1999;54:133–142.
- 2 Moffett-King A: Natural killer cells and pregnancy. *Nat Rev Immunol* 2002;2:656–663.

- 3 Bischof P, Campana A: A model for implantation of the human blastocyst and early placentation. *Hum Reprod Update* 1996; 2/3:262–270.
- 4 Pijnenborg R: The placental bed. *Hypertens Pregnancy* 1996;15:7–23.
- 5 Zhou Y, Fisher SJ, Janatpour M, Genbacev O, Dejana E, Wheelock M, Damsky CH: Human cytotrophoblast adopt a vascular phenotype as they differentiate. A strategy for successful endovascular invasion? *J Clin Invest* 1997;99:2139–2151.
- 6 Saito S, Sakai M: Th1/Th2 balance in preeclampsia. *J Reprod Immunol* 2003;59:161–173.
- 7 Mosmann TR, Sad S: The expanding universe of T-cell subsets: Th1, Th2 and more. *Immunol Today* 1996;17:138–146.
- 8 Swain SL: IL-4 dictates T-cell differentiation. *Res Immunol* 1993;144:616–620.
- 9 Lyall F, Simpson H, Bulmer JN, Barber A, Robson SC: Transforming growth factor- β expression in human placenta and placental bed in third trimester normal pregnancy, preeclampsia, and fetal growth restriction. *Am J Pathol* 2001;159:1827–1838.
- 10 Rinehart BK, Terrone DA, Lagoo-Deenadayalan S, Barber WH, Hale EA, Martin JN, Bennett WA: Expression of the placental cytokines tumor necrosis factor α , interleukin 1 β and interleukin 10 is increased in preeclampsia. *Am J Obstet Gynecol* 1999;181:915–920.
- 11 Anim-Nyame N, Gamble J, Sooranna SR, Johnson MR, Steer PJ: Microvascular permeability is related to circulating levels of tumour necrosis factor- α in pre-eclampsia. *Cardiovasc Res* 2003; 58:162–169.
- 12 Reimer T, Koczan D, Gerber B, Richter D, Theisen HJ, Friese K: Microarray analysis of differentially expressed genes in placental tissue of pre-eclampsia: Up-regulation of obesity related genes. *Mol Hum Reprod* 2002;8:674–680.
- 13 Ashkar AA, DiSanto JP, Croy BA: Interferon-gamma contributes to initiation of uterine vascular modification, decidual integrity, and uterine natural killer cell maturation during normal murine pregnancy. *J Exp Med* 2000;192:259–270.
- 14 Plevyak M, Hanna N, Mayer S, Murphy S, Pinar H, Fast L, Ekerfelt C, Ernerudh J, Berg G, Matthiesen L, Sharma S: Deficiency of decidual IL-10 in first trimester missed abortion: A lack of correlation with the decidual immune cell profile. *Am J Reprod Immunol* 2002;47: 242–250.
- 15 Murphy S, Fast L, Sharma S: IL-10, uterine NK cells, inflammation, and pregnancy. *Am J Reprod Immunol* 2004;51:434.
- 16 Henessy A, Pilmore HL, Simmons LA, Painter DM: A deficiency of placental IL-10 in preeclampsia. *J Immunol* 1999;163:3491–3495.
- 17 Roth I, Fisher SJ: IL-10 is an autocrine inhibitor of human placental cytotrophoblast MMP-9 production and invasion. *Dev Biol* 1999;205:194–204.
- 18 Wegmann TG, Lin H, Guilbert L, Mossman TH: Bidirectional cytokine interactions in the materno-fetal relationship: Is successful pregnancy a Th2 phenomenon? *Immunol Today* 1993; 14:353–355.
- 19 Chaouat G, Ledee-Bataille N, Zourbas S, Dubanchat S, Sandra O, Martal J, Ostojojic S, Frydman R: Implantation: Can immunological parameters of implantation failure be of interest for preeclampsia? *J Reprod Immunol* 2003;59:205–217.
- 20 Sakai M, Ogawa K, Shiozaki A, Yoneda S, Sasaki Y, Nagata K, Saito S: Serum granulysin is a marker for Th1 type immunity in pre-eclampsia. *Clin Exp Immunol* 2004;1:114–119.
- 21 Eneroth E, Remberger M, Vahlne A, Ringden O: Increased serum concentrations of interleukin-2 receptor in the first trimester in women who later developed severe preeclampsia. *Acta Obstet Gynecol Scand* 1998;77:591–593.
- 22 Croy BA, Ashkar AA, Minhas K, Greenwood JD: Can murine uterine natural killer cells give insights into the pathogenesis of pre eclampsia? *J Soc Gynecol Invest* 2000;7:12–20.
- 23 Neale D, Demasio K, Illuzi J, Chaiworapongsa T, Romero R, Mor G: Maternal serum of women with pre-eclampsia reduces trophoblast cell viability: Evidence for an increased sensitivity to Fas-mediated apoptosis. *J Maternal Fetal Neonatal Med* 2003;13:39–44.
- 24 Sargent IL, Germain SJ, Sacks GP, Kumar S, Redman CWG: Trophoblast deportation and the maternal inflammatory response in pre-eclampsia. *J Reprod Immunol* 2003;59:153–160.

- 25 Walker JJ: Antioxidants and inflammatory cell responses in preeclampsia. *Semin Reprod Endocrinol* 1998;16/1:47–55.
- 26 Matthiesen L, Berg G, Ernerudh J, Skogh T: Lymphocyte subsets and autoantibodies in pregnancies complicated by placental disorders. *Am J Reprod Immunol* 1995;33:31–39.
- 27 Jonsson Y, Rubèr M, Matthiesen L, Berg G, Nieminen K, Sharma S, Ernerudh J, Ekerfelt C: Cytokine mapping of serum from women with preeclampsia and from women with normal pregnancy. *Am J Reprod Immunol*, submitted.

Leif Matthiesen
Department of Molecular and Clinical Medicine
Division of Obstetrics and Gynaecology, University Hospital
SE-581 85 Linköping (Sweden), Tel. +46 13 22 31 37
Fax +46 13 14 81 56, E-Mail leif.matthiesen@lio.se