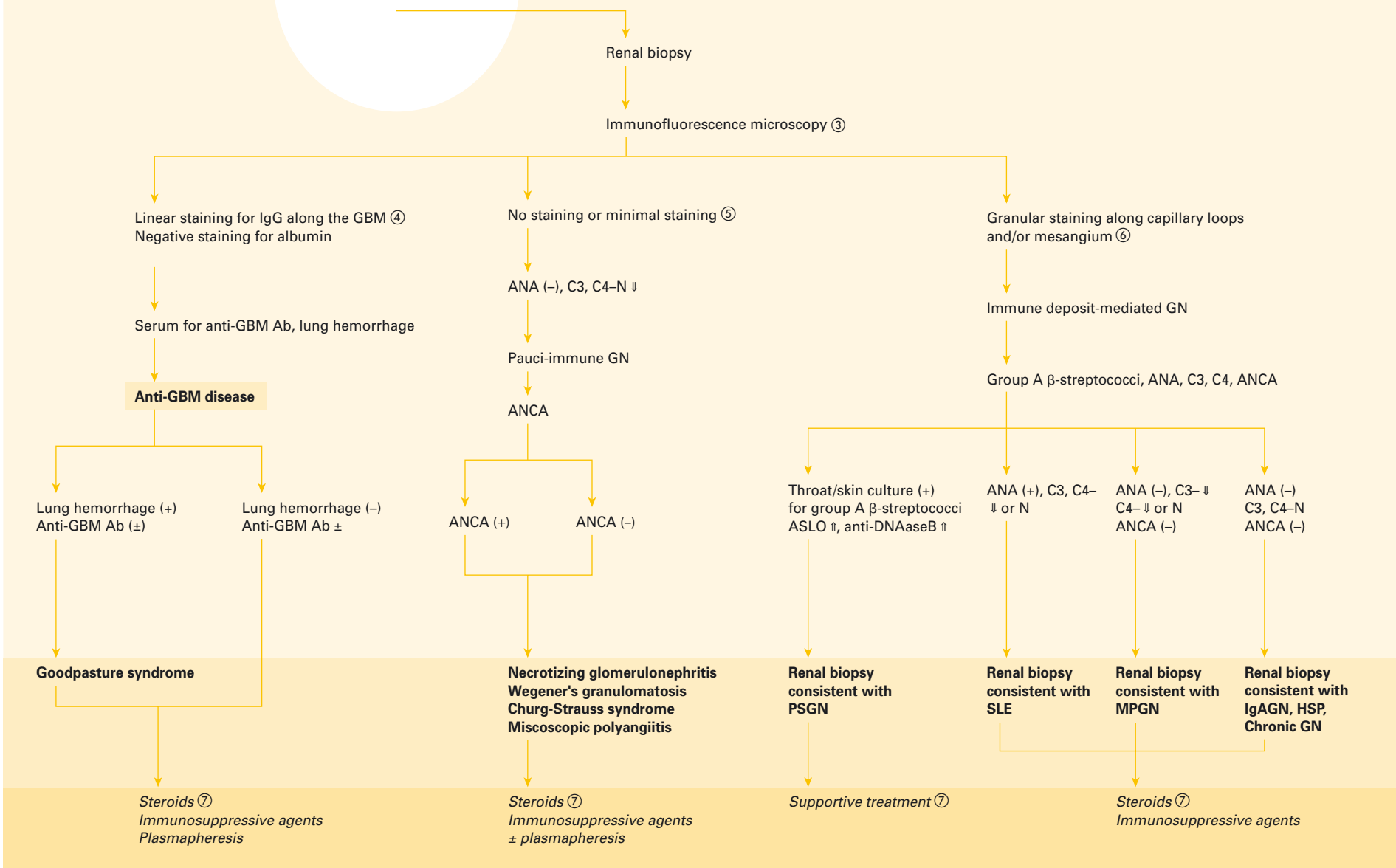


Rapidly progressive glomerulonephritis^{①②}



① — RPGN is a term used to describe proliferative glomerulonephritides with rapidly deteriorating renal function and renal biopsy findings showing diffuse epithelial crescents in greater than 60% of the glomeruli. Because of the presence of crescents, this entity is also called crescentic glomerulonephritis. Of note, several renal disorders can lead to a clinical picture similar to RPGN but without the typical histologic findings. These disorders include conditions such as tubulointerstitial nephritis and acute tubular necrosis.

② — History and physical examination can provide valuable clues towards the type of RPGN. By definition these patients have hematuria, proteinuria, abnormal cellular casts in urine sediment, and renal failure (elevated serum creatinine). Frequently, they also have gross hematuria (brown tea color urine) and/or hypertension and/or NS. These clinical and laboratory features by themselves are not very helpful in uncovering the underlying etiology of RPGN. Previous throat or skin infection (impetigo) with group A β -streptococci, typical rash of HSP, clinical features of SLE (joint pain, skin rash, fever, etc.), hemoptysis (Goodpasture syndrome), and chronic sinusitis (Wegener's) are helpful leading clues.

③ — A renal biopsy is performed and the tissue is processed for histology using HE, PAS, and Jones stains for light microscopy, and for immunofluorescence and transmission electron microscopy. For immunofluorescence, frozen sections are stained with fluorescein-labeled antibodies to human immunoglobulins (IgG, IgM, IgA), complement components (C3, C4 C1q), fibrinogen and albumin. All these studies are necessary for making an accurate diagnosis. Additional laboratory tests including serum ANA, ANCA, AGBMAb, C3 and C4 complement, and tests for group A β -streptococcal infection provide useful leads into the etiology of RPGN.

④ — Anti-GBM disease is a rare disorder, especially in children. It is caused by circulating antibodies (mainly IgG) against GBM in the lungs and kidney glomeruli. Clinical features include RPGN with or without pulmonary hemorrhage (called in the past Goodpasture syndrome and Goodpasture disease, respectively). Typical laboratory findings include reduced renal function, anemia and serum anti-GBM antibodies. Renal biopsy reveals crescentic GN with linear staining for IgG along the GBM. For treatment

modalities, see section (6). The prognosis, which was devastating before the plasmapheresis era, has improved dramatically but still the rates of chronic renal sequelae, ESRD and mortality are high.

⑤ — A subset of children and adults with RPGN will not show either immune deposits or anti-GBM antibodies on renal biopsy. This entity, termed pauci-immune GN, will be accompanied in approximately 80–90% of the cases by a positive test for ANCA in their sera. ANCA(+) RPGN may be associated with small vessel vasculitides (Wegener's granulomatosis, Churg-Strauss syndrome and microscopic polyangiitis) or may be idiopathic with necrotizing glomerulonephritis on biopsy. The antigen specificity of ANCA may be for proteinase 3 or myeloperoxidase. The former produces C-ANCA and the latter P-ANCA staining. 80–90% of ANCA found in Wegener's granulomatosis are C-ANCA. P-ANCA are more often seen in necrotizing glomerulonephritis and polyangiitis. For treatment modalities, see section (5).

⑥ — RPGN resulting from PSGN, despite its severity, resolves spontaneously and does not require immunosuppressive agents or plasmapheresis. Patients with PSGN, however, may require dialysis for a few days. For details on other immune-mediated diseases leading to RPGN (SLE, MPGN, IgAN, HSP, etc.), see the appropriate algorithms.

⑦ — Immunosuppression is generally started with a high dose of intravenous methyl prednisolone (pulse therapy). Common dosages are 15–30 mg/kg (maximum 1,000 mg) given once a day as an infusion in 50–100 ml of 5% dextrose over 1–2 h. Usually, 3 doses are given but 5–6 doses have also been given safely. This is followed by 2 mg/kg/day oral prednisone given in 3–4 divided doses. Cyclophosphamide may be added as an adjunct to therapy and can be given orally at a dosage of 2 mg/kg/day or intravenously at a dose of 500 mg/m² according to the schedule used by the NIH to treat diffuse proliferative glomerulonephritis of SLE. The duration of prednisone and cyclophosphamide therapy is variable and is often individualized depending on the initial response. Plasmapheresis is generally added to the regimen of the above immunosuppression in RPGN resulting from anti-GBM disease particularly if autoantibodies to the GBM are present in serum. In general, the plasmapheresis treatments

are continued until these antibodies disappear from the serum. In most cases of pauci-immune RPGN, plasmapheresis is added to the treatment regimen. The value of plasmapheresis in immune-mediated RPGN is not certain, but it is often used as a last effort in refractory cases.

Selected reading

Dillon MJ: Crescentic glomerulonephritis; in Avner ED, Harmon WE, Niaudet P (eds): Pediatric Nephrology, ed 5. Philadelphia, Lippincott Williams & Wilkins, 2004, pp 655–662.

Fischer EG, Lager DJ: Anti-glomerular basement membrane glomerulonephritis: a morphologic study of 80 cases. Am J Clin Pathol 2006;125:445–450.

Jennette JC, Thomas DB: Crescentic glomerulonephritis. Nephrol Dial Transplant 2001;16 (suppl 6):80–82.

Kallenberg CG: Antineutrophil cytoplasmic autoantibody-associated small-vessel vasculitis. Curr Opin Rheumatol 2007;19:17–24.

Morgan MD, Harper L, Williams J, Savage C: Anti-neutrophil cytoplasm-associated glomerulonephritis. J Am Soc Nephrol 2006;17:1224–1234.