

Supplemental table 1. Questioners which were asked to patients during
and within 3 hours after vitreous surgery

1. Do you see anything?
2. Do you see light?
3. If yes, what color what shape what extension is it?
4. Do you see any object?
5. If yes, how does it look like?

Questions during vitrectomy was asked during each surgical procedure: core vitrectomy, injection of triamcinolone acetonide, membrane peeling, fluid/air exchange, etc .

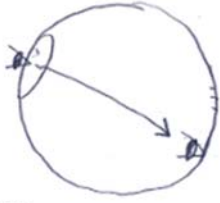
Supplemental table 2. How the patients saw the stick like instruments.

Illumination	Position of the instrument*		Patient's description [§]	
	right hand	left hand	number of the stick seen	position of the stick seen
endoillumination	vitrecous cutter	light probe	1	left side
	light probe	vitrecous cutter	1	right side
operating microscope	vitrecous cutter	light probe	2	both sides
	light probe	vitrecous cutter	2	both sides

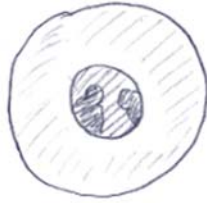*: 'right hand' means scleral port at 10 o'clock and 'left hand' means 2 o'clock.

§: When patient reported "A stick-like material is seen on the left in the visual field", the number was '1' and position was 'left side'.

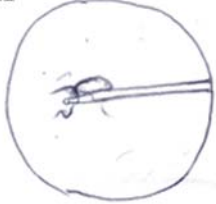I



II



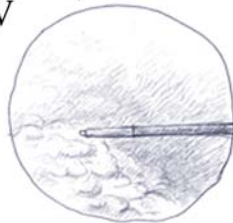
III



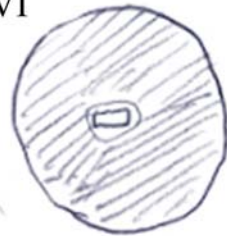
IV



V



VI



VII



VIII



Supplemental figures

The “Report of the surgery on my right eye.” provided by a 55-year-old man who underwent vitrectomy, phacoemulsification, and IOL implantation in the right eye uneventfully for vitreous hemorrhage associated with proliferative diabetic retinopathy.

I. After anesthesia, I felt as if I were looking from bottom of the eye.

II. It became dark and he reported that everything appeared as black and white I could see people faintly.

Beginning of core vitrectomy: I had no idea about the vitreous cutter. Because I wanted to avoid seeing anything, I concentrated on the left eye (unoperated fellow eye).

III. A vessel-like object picked-up and got entangled around a stick-like object. I understood the stick must be a cutter.

IV. Several slim vessel-like objects wafted through the field and it became cloudy. Bleeding occurred three times.

V. The last big-game was removed with the cutter.

During laser treatment: Because it was very bright during the laser treatment, I concentrated on the left eye. The laser seemed blue. I wondered why I could see color.

End of the surgery: At the end of surgery a lens was inserted, then I saw a small square white light up over.

Additional comments:

VI. I felt as if I was in “20,000 leagues under the Sea”. At first I came under strain in the operating room, but music induced me into a relaxed state.

VII. Before surgery, I saw some objects that looked like ‘blood clots’.

VIII. I focused on the edge of the object (indicated by star), it looked like ‘a tail of an Alien.