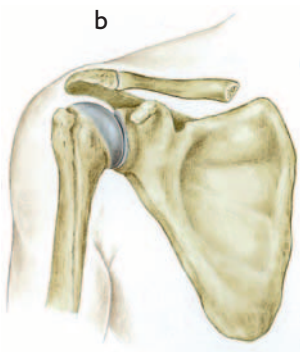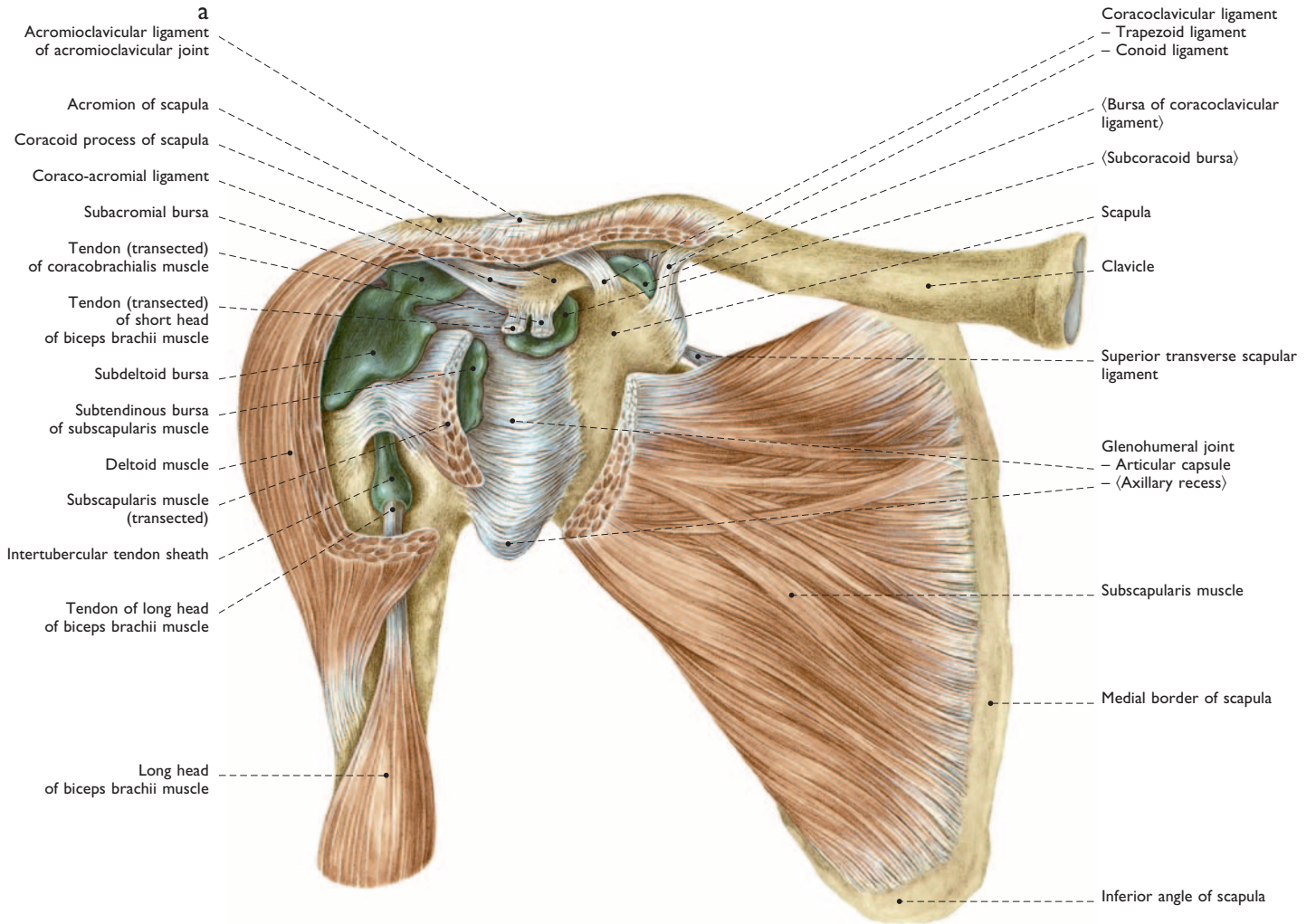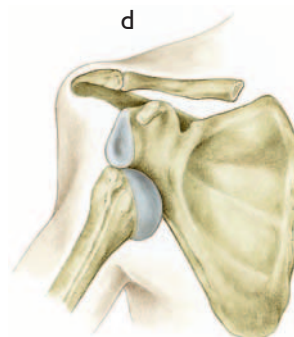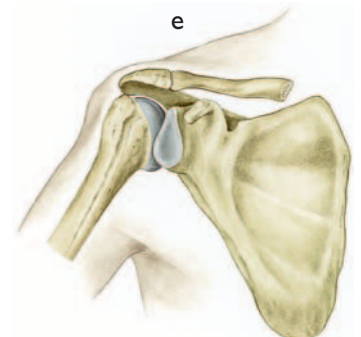


85%



10%



3%

103 Right glenohumeral (= shoulder) joint

Ventral aspect

- a Synovial bursae in the shoulder region (50%)
- b-e Dislocations of the shoulder. The percentile numbers indicate the approximate frequency of occurrence.
- b Normal situation
- c Anterior dislocation of the head of humerus (subcoracoid luxation), most frequent type
- d Inferior dislocation (axillary = subglenoid luxation)
- e Posterior dislocation (subacromial luxation)