

# Spontaneous Bacterial Peritonitis

Todd A. Sheer<sup>a</sup> Bruce A. Runyon<sup>b</sup>

<sup>a</sup>Department of Internal Medicine, Division of Gastroenterology, Naval Medical Center San Diego, San Diego, Calif., and <sup>b</sup>Department of Internal Medicine, Division of Gastroenterology, Loma Linda University Medical Center, Loma Linda, Calif., USA

## Key Words

Spontaneous bacterial peritonitis · Ascites · Cirrhosis · Bacterascites · Paracentesis · Infection

## Abstract

Spontaneous bacterial peritonitis (SBP) is a bacterial infection of ascitic fluid in patients with decompensated cirrhosis. The modifier 'spontaneous' distinguishes this from surgical peritonitis. The infecting organisms are usually enteric gram-negatives which have translocated from the bowel. Symptoms of infection occur in most patients with SBP, including fever, abdominal pain, mental status changes, and ileus. A high index of suspicion should exist for SBP in patients with cirrhosis and ascites. Diagnostic abdominal paracentesis can be undertaken with minimal risk and should be performed in all patients admitted to the hospital, during times of worsening clinical appearance, or when gastrointestinal bleeding occurs. The ascitic fluid polymorphonuclear cell count is the most sensitive test in evaluating for infection. Cultures of the ascitic fluid are helpful in identifying the organism and are best performed by bedside injection of blood culture bottles. Ascites total protein, lactate dehydrogenase, and glucose levels can assist in distinguishing SBP from secondary peritonitis. Empirical therapy is recommended after paracentesis if suspicion for infection exists. Cefotaxime is the best-studied antibiotic for this purpose and has excellent penetration into

ascites with no nephrotoxicity. Prophylaxis should be limited to high-risk settings. Mortality rates in SBP have declined dramatically, largely due to earlier detection and improved therapy.

Copyright © 2005 S. Karger AG, Basel

## Introduction

Spontaneous bacterial peritonitis (SBP) is a potentially fatal yet reversible cause of deterioration in patients with advanced cirrhosis. It is defined as a bacterial infection of the ascitic fluid in the absence of a focal contiguous source; this infection almost universally occurs in the background of severe liver disease [1]. Since its first description by Conn [2] and Kerr et al. [3] in 1963, there has been a significant increase in the understanding of the pathophysiology, diagnosis, treatment, and prophylaxis of the disease.

The prevalence is only 3.5% in asymptomatic outpatients [4], but increases to 10–30% in hospitalized individuals, with half occurring at the time of admission and the other half diagnosed during hospitalization [5]. It is the most frequent infectious complication in patients with cirrhosis, composing one-third of all bacterial infections and is more common than urinary tract infections and pneumonia in this population [6]. SBP developing in the setting of ascites from causes other than cirrhosis is rare [7], but can occur in cardiac ascites [8], nephrogenic

**Table 1.** Variants of ascitic fluid infection

	PMN count cells/mm <sup>3</sup>	Culture
Spontaneous bacterial peritonitis	≥ 250	single organism
Culture-negative neutrocytic ascites	≥ 250	negative
Monomicrobial nonneutrocytic bacterascites	<250	single organism
Secondary bacterial peritonitis	≥ 250	polymicrobial
Polymicrobial bacterascites	<250	polymicrobial

ascites [9], and ascites associated with fulminant hepatic failure [10], and alcoholic and viral hepatitis [11]. Malignant ascites is even less frequently complicated by SBP [12].

Five variants of ascitic fluid infection are described [13], based on the fluid polymorphonuclear leukocyte (PMN) count, culture results, and method of entry of the organism into the fluid (table 1). SBP is the prototype and is most common. It is defined as a PMN count  $\geq 250$  cells/mm<sup>3</sup> in the presence of a single organism on culture. *Monomicrobial nonneutrocytic bacterascites (MNB)* occurs when the PMN count is less than 250 cells/mm<sup>3</sup>, but growth of a single organism is detected on culture. *Culture-negative neutrocytic ascites (CNNA)* is defined as an elevated ascitic fluid PMN count ( $\geq 250$  cells/mm<sup>3</sup>) in the absence of culture growth, obtained prior to the administration of antibiotics. *Secondary bacterial peritonitis* is distinct from the previous subtypes in that the source of the organism is a surgically treatable process such as a perforated viscus or a contained intra-abdominal abscess. In these cases, the PMN count is  $\geq 250$  cells/mm<sup>3</sup> and the culture results are usually polymicrobial. *Polymicrobial bacterascites* presents with a PMN count  $<250$  cells/mm<sup>3</sup>, and as the name suggests, polymicrobial growth on culture. This finding is essentially diagnostic of bowel perforation by the paracentesis needle and reflects growth of gut flora before the ascitic fluid has had the opportunity to mount a neutrocytic response. Fortunately, this is a rare event, occurring in 0.6% or less of paracenteses [14, 15].

### Pathogenesis

Based on the predominance of enteric gram-negative organisms (*Escherichia coli* and *Klebsiella* in over 50% of cases) [16, 17], it has long been suspected that the primary source of infection in SBP is the gut. Cirrhosis appears to lead to intestinal bacterial overgrowth (in a ro-

dent model), possibly through a combination of delayed transit and decreased amounts of luminal IgA and bile salts [18]. Intestinal permeability may be enhanced in cirrhotics with portal hypertension and bowel edema, favoring bacterial translocation into the mesenteric lymph nodes [18]. In the rodent model of cirrhosis, pathogenic bacteria have been cultured from mesenteric lymph nodes in nearly 80% [19]. Intestinal bacterial translocation is organism specific, with gram-negatives translocating more efficiently compared to gram-positives and anaerobes [20]. This likely plays a significant role in the bacteriology of SBP. Bacteria do not directly migrate from the intestinal lumen into the ascitic fluid (except in states of loss of mucosal integrity), otherwise polymicrobial infections would be the predominant presentation rather than the exception. Also, anaerobes, which are a large component of gut flora, are almost never isolated from ascites in primary bacterial peritonitis [17, 21].

Bacteremia then ensues as organisms spill over from the mesenteric lymph nodes into the systemic circulation [22]. Due to deficiencies in the reticuloendothelial system in cirrhotics, the bacteria may persist uncleared in the circulation [23] and eventually colonize the ascitic fluid as infected filtrate weeps off of the surface of the cirrhotic liver or drains from the intestinal capillary beds [1]. Using a PCR-based technique, Such et al. [24] have recently been able to demonstrate the presence of bacterial DNA in the serum and ascitic fluid in one-third of patients admitted with cirrhosis and nonneutrocytic, culture-negative ascites.

The next line of defense is breached as the opsonic or endogenous antimicrobial activity is diminished or nonexistent in low-protein ascites [25]. A prospective study demonstrated that an ascitic fluid total protein concentration of  $\leq 1$  g/dl was a significant risk factor for the development of SBP, with these patients being ten times more likely to develop SBP during hospitalization than those with levels above 1 g/dl [26]. Particularly virulent bacteria such as *Salmonella* can lead to infection even in the

setting of high protein ascites with normal opsonic activity [27]. If the opsonins and macrophage system fail to destroy the bacteria, bacterascites can then progress to neutrocytic ascites as the final line of defense, the neutrophils, are recruited [28]. Unfortunately, patients with advanced liver disease have impaired neutrophil function on many levels [29, 30].

In summary, SBP is the culmination of the inability of the gut to contain bacteria and failure of the immune system to eradicate the organisms once they have escaped (fig. 1) [28]. Depending on where this process is arrested and when it is detected by ascitic fluid sampling determines whether the patient will present with MNB, CNNA, or full-blown SBP.

All cirrhotic patients with ascites are at risk for SBP [5]. However, there are certain additional risk factors which can further increase susceptibility such as the previously mentioned presence of a low ascitic fluid total protein level. Upper gastrointestinal bleeding poses a risk of bacteremia and SBP in the cirrhotic patient with rates of infection ranging from 17 to 21% [31, 32]. Ischemia-reperfusion of the gut during variceal hemorrhage has been proposed to interfere with the normal function of the reticuloendothelial system and to increase the permeability of the intestinal mucosa [33]. Survivors of a prior episode of SBP are at increased risk for recurrence with a one-year probability of almost 70% [34]. It is on the basis of these findings that the recommendations for antimicrobial prophylaxis are made (see later). Paracentesis does not pose a significant risk for ascitic fluid infection, and this specific complication has not been demonstrated in two large series of over 1,300 patients [15, 35]. Minimally invasive procedures such as intravenous and urinary bladder catheters likely predispose to bacteremia and SBP in the cirrhotic, and despite lack of definitive evidence of causality, the procedures should be minimized or avoided [36, 37].

### Clinical Setting

SBP usually occurs at the time of greatest ascites volume, but can be present in settings where the fluid is clinically undetectable. SBP in the absence of ascites is extremely unlikely [22]. The majority of patients with SBP have severe liver dysfunction. Toledo et al. [38] demonstrated that 96% of patients with SBP had either Child-Pugh grade B or C. Most patients with ascitic fluid infection present with symptoms [39]. These most commonly include fever in 50–75%, abdominal pain in 27–72%,

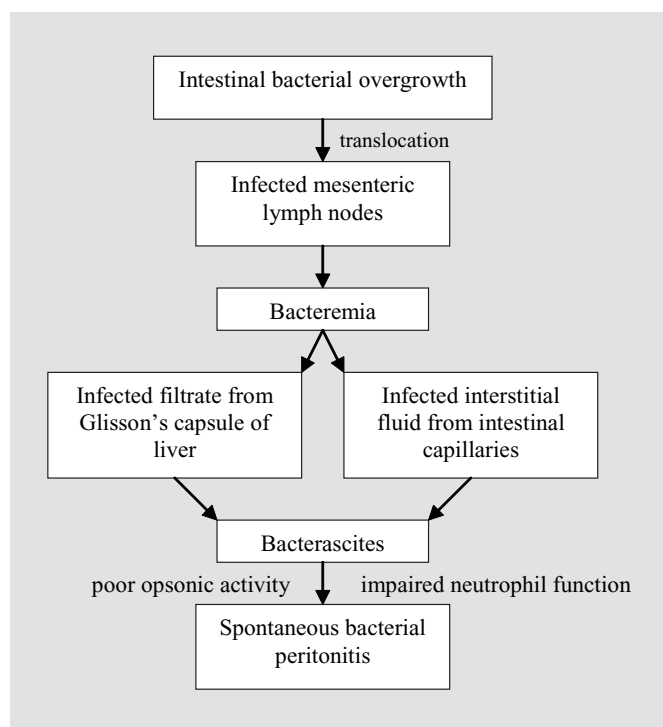


Fig. 1. Pathogenesis of SBP.

chills in 16–29%, and nausea or vomiting in 8–21% [6, 16, 37, 39, 40]. Changes in gastrointestinal motility manifesting as ileus or diarrhea may also be seen [18, 39, 40]. Organ systems outside the gastrointestinal tract can be affected. Mental status changes, which may be subtle, occur in 50% [39, 41], and decrements in renal function are seen in one-third of cases [42]. Shock at the time of presentation is a rare event [38], probably as a result of the current lower threshold to perform diagnostic paracentesis and earlier diagnosis. Up to 13% of patients may be asymptomatic [39]. Physical examination is not as dramatic as in secondary peritonitis in the absence of ascites. The presence of intra-abdominal fluid separates the visceral and parietal peritoneum, and therefore the classic surgical abdomen is not seen, even when frank perforation and gross fecal contamination of the peritoneal cavity occur [43]. As a result, although abdominal tenderness is noted in 30–40% of cases, rebound tenderness is seen only in a few percent [39, 40].

Laboratory evaluation (not including ascitic fluid analysis) is nonspecific. There may be a subtle elevation in the peripheral leukocyte count, an increase in blood urea nitrogen and serum creatinine, or an unexplained metabolic acidosis [40, 42]. Unfortunately, the history, physi-

**Table 2.** Recommended tests of ascitic fluid if infection suspected

---

Cell counts with differential  
Culture (in blood culture bottles)  
Gram's stain  
Total protein  
Lactate dehydrogenase  
Glucose  
Amylase  
Albumin (if SAAG unknown)

---

SAAG = Serum-ascites albumin gradient.

---

cal examination, and serum laboratory testing are not useful in distinguishing SBP, CNNA, and secondary bacterial peritonitis [39, 40, 43].

### Diagnosis

A high index of suspicion must exist for ascitic fluid infection in a cirrhotic patient. Given the similarities in presentation between the variants of ascitic fluid infection and the inability to clinically distinguish spontaneous from secondary peritonitis, the diagnosis of SBP should not be empiric. The threshold to perform diagnostic abdominal paracentesis should accordingly be low, especially as it has been shown to be safe with a low risk for complication, even in patients with marked coagulopathy and thrombocytopenia [15, 35]. A diagnostic paracentesis should be performed in all cirrhotics with ascites and: (1) upon admission to the hospital, (2) who develop any change in clinical status including fever, abdominal pain, mental status changes, ileus, or septic shock, (3) who develop laboratory abnormalities such as a leukocytosis, acidosis, or renal failure, or (4) during episodes of gastrointestinal bleeding prior to the administration of antibiotics [5, 44].

When suspicion of infection exists, ascitic fluid should be sent for cell counts, total protein, glucose, lactate dehydrogenase, amylase, Gram's stain, and culture. A serum and ascitic fluid albumin should also be sent if the serum-ascites albumin gradient has not been previously calculated (table 2). Other tests such as ascitic fluid pH and lactate are of limited value and more confusing than helpful [45]. The fluid PMN count (when using a threshold of 250 cells/mm<sup>3</sup>) is the most sensitive and single best

test in diagnosing ascitic fluid infection [45]. Not all cases in which the PMN count is above this threshold represent infection, and values in this range can be seen with hemorrhage into ascites, peritoneal carcinomatosis, or pancreatic ascites [13]. A useful distinguishing feature is that the PMN is usually not the predominant cell type in these cases. Peripheral leukocytosis does not affect the ascitic fluid total leukocyte or PMN count [46]. Recently, the use of urine reagent strips to test for leukocyte esterase in ascitic fluid has demonstrated an accuracy of 97% in predicting a PMN count above 250 cells/mm<sup>3</sup> [47]. Given the rapid processing time (90 s), low cost, and availability, 'dipstick' testing of ascites may allow for more rapid diagnosis and management of SBP in the future.

Secondary bacterial peritonitis should be suspected if the ascites PMN count is  $\geq 250$  cells/mm<sup>3</sup> and two of the following three ascitic fluid values are met: (1) glucose  $< 50$  mg/dl, (2) total protein  $> 1$  g/dl, and (3) lactate dehydrogenase greater than the upper limit of normal for serum [43]. Gut perforation can be predicted with 100% sensitivity (but only 45% specificity) using these criteria [43]. Nonetheless, patients who fulfill two of these criteria must undergo immediate flat and upright abdominal X-rays, and if negative, water-soluble contrast studies of the gastrointestinal tract or abdominal computed tomography [44]. The finding of more than one organism on Gram's stain or culture of ascitic fluid should prompt a similar urgent evaluation for perforation [44]. If multiple organisms are detected on either modality but the PMN count is  $< 250$  cells/mm<sup>3</sup>, the diagnosis is likely polymicrobial bacterascites due to puncture of the bowel with the paracentesis needle. This is a rare occurrence (less than 0.6% of paracenteses), is associated with low morbidity, and surgical intervention does not appear to be necessary [14].

Given the low bacterial burden in SBP (median concentration of one organism per milliliter), the conventional method of culturing ascitic fluid on agar plates in the laboratory is insensitive. A prospective study comparing conventional culture methods to the bedside inoculation of blood culture bottles with 10 ml of ascitic fluid demonstrated an increase in sensitivity from 43 to 93% as well as a more rapid detection of bacterial growth with the latter technique [17]. The yield of blood culture bottles is higher if inoculated at the bedside compared to sending a syringe to the laboratory for later inoculation [21].

## Treatment

Empirical antibiotic therapy for SBP should begin as soon as infection is suspected (i.e. PMN count  $\geq 250$  cells/mm<sup>3</sup>) and not delayed pending culture confirmation of the organism and sensitivities [48]. Delaying treatment until the results of the culture are known may result in death of the patient from overwhelming sepsis [44]. Accordingly, patients with CNNA also warrant early antibiotic therapy as they are similar to SBP with regard to symptoms, ascitic fluid analysis, rate of blood culture growth, and mortality [40]. In one prospective study of 44 patients with MNB [39], 62% resolved without progression to SBP and without antibiotic therapy. The remainder progressed to SBP, some with an interval as short as 40 min, before the initiation of treatment. The only distinguishing feature between the two groups was the presence of signs or symptoms of infection in the group that progressed to SBP. Therefore, patients with a clinical presentation suggesting infection, even with an initial ascitic fluid PMN count  $<250$  cells/mm<sup>3</sup>, should be treated with empirical antibiotics [41, 44]. As soon as the ascitic fluid culture returns demonstrating growth of bacteria, a repeat paracentesis should be performed if antibiotics had not been started (i.e. patient was asymptomatic and the ascites was initially nonneutrocytic). If the second ascitic fluid PMN count is  $\geq 250$  cells/mm<sup>3</sup>, if the repeat culture remains positive, or if the patient has developed symptoms, treatment should be initiated [5, 13].

In cases of standard SBP, a repeat paracentesis to assess for a decline in PMN count or sterilization of culture is not necessary unless there are clinical signs of deterioration on treatment or the initial ascitic fluid analysis revealed atypical findings [44].

Initial therapy should be with a relatively broad-spectrum agent which covers the most common isolates (*Escherichia coli*, *Klebsiella pneumoniae*, and pneumococci) [44]. Cefotaxime has been the most extensively studied antibiotic and, at a dose of 2 g intravenously every 8 h, it rapidly enters the ascitic fluid and exceeds the MIC of 90% of the isolated organisms by 20-fold [49]. Cefotaxime and its active metabolite have essentially 100% penetration into ascitic fluid and are able to sterilize the fluid in 94% of cases after a single dose [49]. Furthermore, cefotaxime has been proven to be significantly more effective in resolving the infection with no risk of nephrotoxicity when compared to ampicillin-tobramycin [50]. Loading doses or intraperitoneal injection of cefotaxime are not necessary [49], and a 5-day course appears to be

as effective as a 10-day course [52]. Resolution of SBP is expected in 83–93% of patients treated with cefotaxime [50–53]. Amoxicillin-clavulanic acid (initially given intravenously followed by oral administration when the patient's condition allowed) has been shown in a single small study to be as effective as cefotaxime (given 1 g intravenously every 6 h) [53]. Due to the risk of nephrotoxicity, aminoglycosides should be avoided in the treatment of SBP [54]. Oral ofloxacin has been investigated and was found to be less expensive and as effective as cefotaxime [51]. However, this study investigated a highly selected population of SBP patients, and those with grade II encephalopathy or higher, creatinine  $\geq 3$  mg/dl, gastrointestinal hemorrhage, ileus, septic shock, or recent use of prophylactic antibiotics were excluded. The treatment of patients with a potentially life-threatening infection using outpatient oral antibiotics is controversial, especially as 50% of patients with SBP have concomitant bacteremia, compliance cannot be assured, and serial examinations and repeat ascitic fluid analysis are difficult [48]. Perhaps an initial course of inpatient intravenous antibiotics for several days followed by outpatient oral therapy once the stability of the patient is assured would be a reasonable option, but is one that still needs further evaluation in future prospective studies [48, 55]. Patients suspected to have secondary bacterial peritonitis should additionally be placed on antibiotics with enterococcal and anaerobic coverage [5, 44] and undergo laparotomy if a surgical source of infection is confirmed on radiologic investigation [43].

Intravenous albumin at a dose of 1.5 g/kg on day 1 and 1 g/kg on day 3 in patients hospitalized for SBP reduced the short- and intermediate-term mortality significantly in a single prospective randomized trial [56]. Although this study was not blinded or placebo-controlled, it does demonstrate the lowest mortality in hospitalized patients with SBP to date, and in the absence of data suggesting otherwise, administration of albumin in this setting is encouraged [44].

## Prophylaxis

General measures to improve the patient's overall medical condition such as abstinence from alcohol and improvement in nutritional status should be attempted. Reduction in the volume of ascites using diuretic therapy has been demonstrated to increase the ascitic fluid total protein level [57] and should theoretically decrease the risk of infection by way of higher opsonic activity [25,

26]. Screening for and prophylaxis of esophageal varices to reduce the risk of gastrointestinal hemorrhage are also recommended. Patients surviving an episode of SBP should be considered for liver transplantation if acceptable candidates [5].

As mentioned previously, certain subgroups of patients with cirrhosis and ascites are at increased risk for the development of SBP, including those with: (1) upper gastrointestinal bleeding, (2) prior episodes of SBP, and (3) low protein ( $\leq 1$  g/dl) ascites. Norfloxacin, a minimally absorbed oral quinolone antibiotic, given at a dose of 400 mg/day for 7 days, has been shown to reduce the risk of ascitic fluid infection and bacteremia in cirrhotic patients hospitalized for gastrointestinal bleeding in a prospective randomized trial [32]. Of note in this study was the fact that most of the infections in the norfloxacin group were caused by gram-positive organisms. A meta-analysis of five randomized controlled trials including 534 patients investigating the use of short-term prophylactic antibiotic therapy in patients with cirrhosis and gastrointestinal bleeding demonstrated a significant decrease in bacterial infections (including SBP) and a 9% improvement in survival in the antibiotic-treated group [58].

Patients who have survived an episode of SBP have a 70% chance of recurrence at one year [34]. In this group, both norfloxacin (400 mg/day) and trimethoprim-sulfamethoxazole (one double-strength tablet/day, daily) given long-term have been shown to reduce recurrence [34, 59]. Trimethoprim-sulfamethoxazole is substantially less expensive than norfloxacin [59].

The use of selective intestinal decontamination (SID) with norfloxacin in patients admitted to the hospital with low-protein ascites has also shown a reduction in the incidence of SBP from 22.5 to 0% [60]. Expanding on this, Novella et al. [61] compared long-term daily norfloxacin prophylaxis to norfloxacin given only during hospitalization in patients with low-protein ascites and found a reduction in community-acquired (but not hospital-acquired) SBP in the continuous therapy group. However, 90% of the *Escherichia coli* isolated from the infections in the continuous treatment arm were resistant to norfloxacin. Fortunately, these organisms retain their sensitivity to cefotaxime [62, 63], but this emphasizes the concept that patients who develop SBP on quinolone prophylaxis should not receive these drugs for treatment but instead undergo treatment with a third-generation cephalosporin (i.e. cefotaxime) [48, 51, 55].

The clinical effect of this shift in the flora of SBP to gram-positive and quinolone-resistant gram-negative or-

ganisms has been questioned in a retrospective review which revealed that SID did not appear to affect the presentation, ascitic fluid analysis, response to empiric cefotaxime, incidence of renal insufficiency, and mortality in patients with SBP [63]. Regardless, antibiotic prophylaxis should be restricted to high-risk patients; namely those with gastrointestinal hemorrhage (short-term), a prior episode of SBP (long-term), or those with ascitic fluid total protein levels  $\leq 1$  g/dl [44]. Whether the latter group should receive long-term or inpatient-only prophylaxis needs careful assessment of the risks and benefits on a case-by-case basis.

### Prognosis

The prognosis of SBP has improved dramatically since its first description. Inpatient mortality has declined from 100% in the 1960s [2] to 60–70% in the 1970s and 1980s [16, 40] to 30% or less in studies performed in the past 10 years [42, 53, 56]. This is likely due to earlier detection and effective, nontoxic therapy. Approximately half of all deaths in patients with SBP occur after resolution of the infection and are from gastrointestinal hemorrhage or liver or renal failure [38, 42]. One study showed an overall mortality of 37.8% in patients admitted with SBP, but only 2.2% were directly attributable to infection [52].

The presence of renal insufficiency is the strongest independent prognostic indicator [38, 42, 55], but the presence of peripheral leukocytosis [38, 55], older age [38, 51], higher Child-Pugh score [38], and the presence of an ileus [38] have also been shown to predict inpatient mortality. Patients with hospital- versus community-acquired SBP also appear to have a higher mortality [4, 38]. The existence of a positive ascitic fluid culture or bacteremia did not influence prognosis [38, 52]. SBP has evolved from a universally fatal disease to a reversible and even preventable cause of deterioration or death in a patient with advanced cirrhosis.

## References

- 1 Hoefs JC, Runyon BA: Spontaneous bacterial peritonitis. *Dis Mon* 1985;31:1-48.
- 2 Conn HO: Spontaneous peritonitis and bacteremia in Laennec's cirrhosis caused by enteric organisms: A relatively common but rarely recognized syndrome. *Ann Intern Med* 1964;60:568-580.
- 3 Kerr DN, Pearson DT, Read AE: Infection of ascitic fluid in patients with hepatic cirrhosis. *Gut* 1963;4:394-398.
- 4 Evans LT, Kim WR, Poterucha JJ, Kamath PS: Spontaneous bacterial peritonitis in asymptomatic outpatients with cirrhotic ascites. *Hepatology* 2003;37:897-901.
- 5 Rimola A, Garcia-Tsao G, Navasa M, Piddock LJ, Planas R, Bernard B, Inadomi JM: Diagnosis, treatment and prophylaxis of spontaneous bacterial peritonitis: A consensus document. *J Hepatol* 2000;32:142-153.
- 6 Caly WR, Strauss E: A prospective study of bacterial infections in patients with cirrhosis. *J Hepatol* 1993;18:353-358.
- 7 Runyon BA: Ascites and spontaneous bacterial peritonitis; in Feldman M, Friedman LS, Sleisenger MH (eds): *Gastrointestinal and liver disease: Pathophysiology/diagnosis/management*, ed 7. Philadelphia, Saunders, 2002, pp 1517-1542.
- 8 Runyon BA: Spontaneous bacterial peritonitis associated with cardiac ascites. *Am J Gastroenterol* 1984;79:796.
- 9 Kato A, Ohtake T, Furuya R, Nakajima T, Ohura M, Kumagai H, Kimura M, Hishida A, Kaneko E: Spontaneous bacterial peritonitis in an adult patient with nephritic syndrome. *Intern Med* 1993;32:719-721.
- 10 Dhiman RK, Makharia GK, Jain S, Chawla Y: Ascites and spontaneous bacterial peritonitis in fulminant hepatic failure. *Am J Gastroenterol* 2000;95:233-238.
- 11 Thomas FB, Fromkes JJ: Spontaneous bacterial peritonitis associated with acute viral hepatitis. *J Clin Gastroenterol* 1982;4:259-262.
- 12 Kurtz RC, Bronzo RL: Does spontaneous bacterial peritonitis occur in malignant ascites? *Am J Gastroenterol* 1982;77:146-148.
- 13 Such J, Runyon BA: Spontaneous bacterial peritonitis. *Clin Infect Dis* 1998;27:669-676.
- 14 Runyon BA, Hoefs JC, Canawati HN: Polymicrobial bacterascites: A unique entity in the spectrum of infected ascitic fluid. *Arch Intern Med* 1986;146:2173-2175.
- 15 Grabau CM, Crago SF, Hoff LK, Simon JA, Melton CA, Ott BJ, Kamath PS: Performance standards for therapeutic abdominal paracentesis. *Hepatology* 2004;40:484-488.
- 16 Correia JP, Conn HO: Spontaneous bacterial peritonitis in cirrhosis: Endemic or epidemic? *Med Clin N Am* 1975;59:963-981.
- 17 Runyon BA, Canawati HN, Akriviadis EA: Optimization of ascitic fluid culture technique. *Gastroenterology* 1988;95:1351-1355.
- 18 Guarner C, Runyon BA, Young S, Heck M, Sheikh MY: Intestinal bacterial overgrowth and bacterial translocation in cirrhotic rats with ascites. *J Hepatol* 1997;26:1372-1378.
- 19 Runyon BA, Squier S, Borzio M: Translocation of gut bacteria in rats with cirrhosis to mesenteric lymph nodes partially explains the pathogenesis of spontaneous bacterial peritonitis. *J Hepatol* 1994;21:792-796.
- 20 Steffen EK, Berg RD, Deitch EA: Comparison of translocation rates of various indigenous bacteria from the gastrointestinal tract to the mesenteric lymph node. *J Infect Dis* 1988;157:1032-1038.
- 21 Runyon BA, Antillon MR, Akriviadis EA, McHutchison JG: Bedside inoculation of blood culture bottles with ascitic fluid is superior to delayed inoculation in the detection of spontaneous bacterial peritonitis. *J Clin Microbiol* 1990;28:2811-2812.
- 22 Runyon BA: Approach to the patient with ascites; in Yamada T, Alpers DH, Laine L, Owyang C, Powell DW (eds): *Textbook of Gastroenterology*, ed 3. Philadelphia, Lippincott, Williams & Wilkins, 1999, pp 966-991.
- 23 Rimola A, Soto R, Bory F, Arroyo V, Piera C, Rodes J: Reticuloendothelial system phagocytic activity in cirrhosis and its relation to bacterial infections and prognosis. *Hepatology* 1984;4:53-58.
- 24 Such J, Frances R, Munoz C, Zapater P, Casellas JA, Cifuentes A, Rodriguez-Valera F, Pascual S, Sola-Vera J, Carnicer F, Uceda F, Palazon JM, Perez-Mateo M: Detection and identification of bacterial DNA in patients with cirrhosis and culture-negative, nonneutrocytic ascites. *Hepatology* 2002;36:135-141.
- 25 Runyon BA, Morrissey RL, Hoefs JC, Wyle FA: Opsonic activity of human ascitic fluid: A potentially important protective mechanism against spontaneous bacterial peritonitis. *Hepatology* 1985;5:634-637.
- 26 Runyon BA: Low-protein-concentration ascitic fluid is predisposed to spontaneous bacterial peritonitis. *Gastroenterology* 1986;91:1343-1346.
- 27 Woolf GM, Runyon BA: Spontaneous salmonella infection of high-protein non-cirrhotic ascites. *J Clin Gastroenterol* 1990;12:430-432.
- 28 Runyon BA: Early events in spontaneous bacterial peritonitis (comment). *Gut* 2004;53:782-784.
- 29 Fiuzza C, Salcedo M, Clemente G, Tellado JM: Granulocyte colony-stimulating factor improves deficient in vitro neutrophil transendothelial migration in patients with advanced liver disease. *Clin Diagn Lab Immunol* 2002;9:433-439.
- 30 DeFernandez MA, Clark A, Triger DR: Neutrophil phagocytic and bacterial function in primary biliary cirrhosis and other chronic liver diseases. *Clin Exp Immunol* 1987;67:655-661.
- 31 Rimola A, Bory F, Teres J, Perez-Ayuso RM, Arroyo V, Rodes J: Oral, nonabsorbable antibiotics prevent infection in cirrhotics with gastrointestinal hemorrhage. *Hepatology* 1985;5:463-467.
- 32 Soriano G, Guarner C, Tomas A, Villanueva C, Torras X, Gonzalez D, Sainz S, Anguera A, Cusso X, Balanzo J, Vilardell F: Norfloxacin prevents bacterial infection in cirrhotics with gastrointestinal hemorrhage. *Gastroenterology* 1992;103:1267-1272.
- 33 Pardy BJ, Spencer RC, Dudley HA: Hepatic reticuloendothelial protection against bacteremia in experimental hemorrhagic shock. *Surgery* 1977;81:193-197.
- 34 Gines P, Rimola A, Planas R, Vargas V, Marco F, Almena M, Forne M, Miranda ML, Llach J, Salmeron JM, Esteve M, Marques JM, Jimenez de Anta MT, Arroyo V, Rodes J: Norfloxacin prevents spontaneous bacterial peritonitis recurrence in cirrhosis: Results of a double-blind, placebo-controlled trial. *Hepatology* 1990;12:716-724.
- 35 Runyon BA: Paracentesis of ascitic fluid: A safe procedure. *Arch Intern Med* 1986;146:2259-2261.
- 36 Guarner C, Soriano G: Spontaneous bacterial peritonitis. *Semin Liver Dis* 1997;17:203-217.
- 37 Carey WD, Boayke A, Leatherman J: Spontaneous bacterial peritonitis: Clinical and laboratory features with reference to hospital-acquired cases. *Am J Gastroenterol* 1986;81:1156-1161.
- 38 Toledo C, Salmeron J, Rimola A, Navasa M, Arroyo V, Llach J, Gines A, Gines P, Rodes J: Spontaneous bacterial peritonitis in cirrhosis: Predictive factors of infection resolution and survival in patients treated with cefotaxime. *Hepatology* 1993;17:251-257.
- 39 Runyon BA: Monomicrobial nonneutrocytic bacterascites: A variant of spontaneous bacterial peritonitis. *Hepatology* 1990;12:710-715.
- 40 Runyon BA, Hoefs JC: Culture-negative neutrocytic ascites: A variant of spontaneous bacterial peritonitis. *Hepatology* 1984;4:1209-1211.
- 41 Pelletier G, Lesur G, Ink O, Hagege H, Attali P, Buffet C, Etienne J: Asymptomatic bacterascites: Is it spontaneous bacterial peritonitis? *Hepatology* 1991;14:112-115.
- 42 Follo A, Llovet JM, Navasa M, Planas R, Forns X, Francitorra A, Rimola A, Gassull MA, Arroyo V, Rodes J: Renal impairment after spontaneous bacterial peritonitis in cirrhosis: Incidence, clinical course, predictive factors and prognosis. *Hepatology* 1994;20:1495-1501.
- 43 Akriviadis EA, Runyon BA: Utility of an algorithm in differentiating spontaneous from secondary bacterial peritonitis. *Gastroenterology* 1990;98:127-133.
- 44 Runyon BA: Management of adult patients with ascites due to cirrhosis. *Hepatology* 2004;39:841-856.

- 45 Runyon BA, Antillon MR: Ascitic fluid pH and lactate: Insensitive and nonspecific tests in detecting ascitic fluid infection. *Hepatology* 1991;13:929-935.
- 46 Antillon MR, Runyon BA: Effect of marked peripheral leukocytes on the leukocyte count in ascites. *Arch Intern Med* 1991;151:509-510.
- 47 Castellote J, Lopez C, Gornals J, Tremosa G, Farina ER, Baliellas C, Domingo A, Xiol X: Rapid diagnosis of spontaneous bacterial peritonitis by use of reagent strips. *Hepatology* 2003;37:893-896.
- 48 Garcia-Tsao G: Treatment of spontaneous bacterial peritonitis with oral ofloxacin: inpatient or outpatient therapy? (letter). *Gastroenterology* 1996;111:1147-1149.
- 49 Runyon BA, Akriviadis EA, Sattler FR, Cohen J: Ascitic fluid and serum cefotaxime and desacetyl cefotaxime levels in patients treated for bacterial peritonitis. *Dig Dis Sci* 1991;36:1782-1786.
- 50 Felisart J, Rimola A, Arroyo V, Perez-Ayuso RM, Quintero E, Gines P, Rodes J: Cefotaxime is more effective than ampicillin-tobramycin in cirrhotics with severe infections. *Hepatology* 1985;5:457-462.
- 51 Navasa M, Follo A, Llovet JM, Clemente G, Vargas V, Rimola A, Marco F, Guarner C, Forne M, Planas R, Banares R, Castellans L, Jimenez De Anta MT, Arroyo V, Rodes J: Randomized, comparative study of oral ofloxacin versus intravenous cefotaxime in spontaneous bacterial peritonitis. *Gastroenterology* 1996;111:1011-1017.
- 52 Runyon BA, McHutchison JG, Antillon MR, Akriviadis EA, Montano AA: Short-course versus long-course antibiotic treatment of spontaneous bacterial peritonitis. *Gastroenterology* 1991;100:1737-1742.
- 53 Ricart E, Soriano G, Novella MT, Ortiz J, Sabat M, Kolle L, Sola-Vera J, Minana J, Dedeu JM, Gomez C, Barrio JL, Guarner C: Amoxicillin-clavulanic acid versus cefotaxime in the therapy of bacterial infections in cirrhotic patients. *J Hepatol* 2000;32:596-602.
- 54 Hampel H, Bynum GD, Zamora E, El-Serag H: Risk factors for the development of renal dysfunction in hospitalized patients with cirrhosis. *Am J Gastroenterol* 2001;96:2206-2210.
- 55 Terg R, Cobas S, Fassio E, Landeira G, Rios B, Vasen W, Abecasis R, Rios H, Guevara M: Oral ciprofloxacin after a short course of intravenous ciprofloxacin in the treatment of spontaneous bacterial peritonitis: Results of a multicenter, randomized study. *J Hepatol* 2000;33:564-569.
- 56 Sort P, Navasa M, Arroyo V, Aldeguer X, Planas R, Ruiz-del-Arbol L, Castells L, Vargas V, Soriano G, Guevara M, Gines P, Rodes J: Effect of intravenous albumin on renal impairment and mortality in patients with cirrhosis and spontaneous bacterial peritonitis. *N Engl J Med* 1999;341:403-409.
- 57 Hoefs JC: Increase in ascites white blood cell and protein concentrations during diuresis in patients with chronic liver disease. *Hepatology* 1981;1:249-254.
- 58 Bernard B, Grange J, Khac EN, Amiot X, Opolon P, Poynard T: Antibiotic prophylaxis for the prevention of bacterial infections in cirrhotic patients with gastrointestinal bleeding: A meta-analysis. *Hepatology* 1999;29:1655-1661.
- 59 Singh N, Gayowski T, Yu VL, Wagener MM: Trimethoprim-sulfamethoxazole for the prevention of spontaneous bacterial peritonitis in cirrhosis: a randomized trial. *Ann Intern Med* 1995;122:595-598.
- 60 Soriano G, Guarner C, Teixido M, Such J, Barrios J, Enriquez J, Vilardell F: Selective intestinal decontamination prevents spontaneous bacterial peritonitis. *Gastroenterology* 1991;100:477-481.
- 61 Novella M, Sola R, Soriano G, Andreu M, Gana J, Ortiz J, Coll S, Sabat M, Vila MC, Guarner C, Vilardell F: Continuous versus inpatient prophylaxis of the first episode of spontaneous bacterial peritonitis with norfloxacin. *Hepatology* 1997;25:532-536.
- 62 Ortiz J, Vila MC, Soriano G, Minana J, Gana J, Mirelis B, Novella MT, Coll S, Sabat M, Andreu M, Prats G, Sola R, Guarner C: Infections caused by *Escherichia coli* resistant to norfloxacin in hospitalized cirrhotic patients. *Hepatology* 1999;29:1064-1069.
- 63 Llovet JM, Rodriguez-Iglesias P, Moitinho E, Planas R, Bataller R, Navasa M, Menacho M, Pardo A, Castells A, Cabre E, Arroyo V, Gasull MA, Rodes J: Spontaneous bacterial peritonitis in patients with cirrhosis undergoing selective intestinal decontamination. *J Hepatol* 1997;26:88-95.