

Pseudomyxoma Peritonei Accompanied by Intraductal Papillary Mucinous Neoplasm of the Pancreas

Yohei Mizuta^a Yuko Akazawa^a Ken Shiozawa^a Hiroshi Ohara^a
Kazuo Ohba^a Ken Ohnita^a Hajime Isomoto^a Fuminao Takeshima^a
Katsuhisa Omagari^a Kenji Tanaka^b Tohru Yasutake^b Tohru Nakagoe^b
Kenji Shirono^c Shigeru Kohno^a

^aSecond Department of Internal Medicine, and ^bFirst Department of Surgery, Nagasaki University School of Medicine, ^cDepartment of Internal Medicine, Shimabara Hospital, Nagasaki, Japan

Key Words

Intraductal papillary mucinous neoplasm ·
Intraperitoneal hyperthermic chemoperfusion ·
Pseudomyxoma peritonei

Abstract

We describe a case of pseudomyxoma peritonei (PMP) successfully managed with intraperitoneal hyperthermic chemoperfusion. This case is unique due to the concurrent presence of intraductal papillary mucinous neoplasm (IPMN) of the pancreas. The patient presented with abdominal fullness. Abdominal computed tomography revealed massive ascites, thickened peritoneum, and a cystic lesion of the pancreas. Cytological examination of ascitic fluid sample showed mucin-rich atypical cells. Endoscopic retrograde pancreatography revealed a cystic lesion with the defect probably due to mural nodule and mucin, communicating with the pancreatic duct. At exploratory laparotomy, massive ascites and multiple nodules were identified within the peritoneal cavity. No primary tumour, including mucinous neoplasm of the appendix, was found. Histopathological examination of the omentum showed mucinous adenocarcinoma in

pools of mucoid material, consistent with PMP. The relation between PMP and IPMN of the pancreas was possible, but not conclusive. The patient received intraperitoneal perfusion of saline heated to 42°C containing cisplatin, etoposide, and mitomycin C, followed by 24 courses of postoperative chemotherapy with gemcitabine. The patient remains in good general condition with no signs of progression of PMP for 2 years, but with a gradual and progressive enlargement of the pancreatic cystic lesion.

Copyright © 2005 S. Karger AG, Basel and IAP

Introduction

Pseudomyxoma peritonei (PMP) is an uncommon neoplastic condition characterized by the seeding of the peritoneum by mucin-secreting tumour cells and accumulation of mucin in the peritoneal cavity [1, 2]. Since the first report by Rokitsky in 1842 [3], the most common underlying causes of this condition are mucinous neoplasms of the appendix and ovary [1, 2]. On the other hand, intraductal papillary mucinous neoplasm (IPMN) of the pancreas is characterized clinicopathologically by

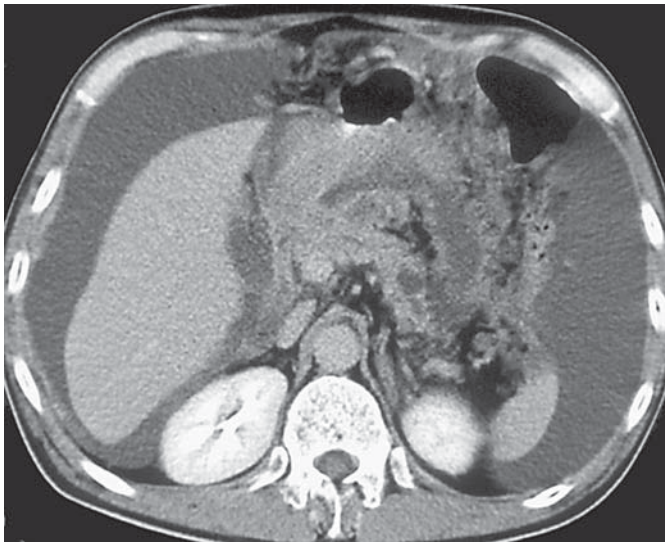


Fig. 1. Computed tomography showing massive ascites, omental cake, thickened peritoneum, and cystic lesion of the pancreas.

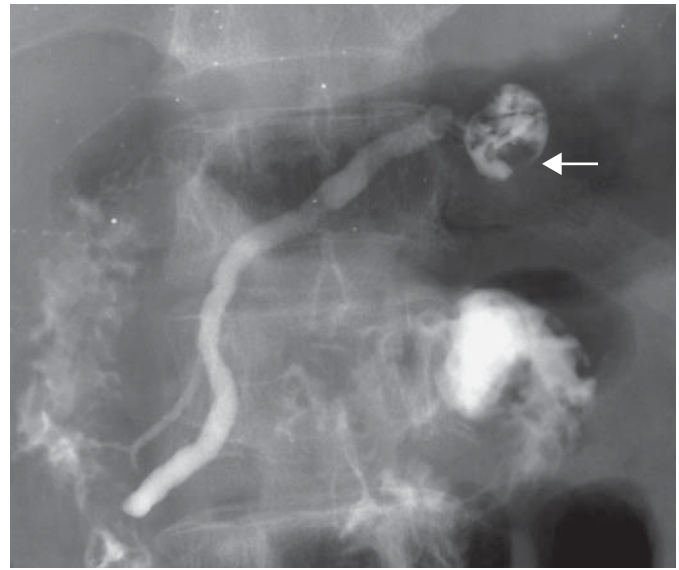


Fig. 2. Endoscopic retrograde pancreatography showing mild dilatation of the pancreatic duct and the cystic lesion with filling defects probably due to mural nodule (arrow) and mucous plaques.

papillary growth and mucin production within the pancreatic duct system [4, 5]. With regard to the combination of both mucinous neoplasms, only a single case of PMP associated with leakage of pancreatic duct mucus by operation of IPMN has been reported [6]. In this report, we describe an unusual case of PMP accompanied by IPMN of the pancreas, in which PMP was successfully treated by intraperitoneal hyperthermic chemoperfusion (IHCP) with cisplatin, etoposide, and mitomycin C, followed by intravenous gemcitabine administration.

Case Report

A 53-year-old man was admitted to our hospital on February 28, 2002 because of abdominal fullness and loss of appetite. There was no history of chronic alcohol abuse, steatorrhea, diabetes, or appendectomy. Family history, including pancreatic disease, was not remarkable. On admission, physical examination showed distended abdomen and massive ascites. Laboratory data showed hypoproteinaemia (total protein, 6.1 g/dl; normal, 6.7–8.3 g/dl) and mild elevation of C-reactive protein (0.88 mg/dl; normal, <0.17 mg/dl), carbohydrate antigen 19–9 (CA19–9, 40 U/ml; normal, <37 U/ml), hyaluronic acid (64 ng/ml; normal, <50 ng/ml) and carbohydrate antigen 125 (CA125, 123 U/ml; normal, <28.1 U/ml). Other routine haematological and biochemical tests were within the normal limits. Abdominal ultrasonography and computed tomography showed massive ascites throughout the peritoneal space, with omental cake and a generalized thickening of the peritoneum, and a cystic lesion in the pancreatic tail (fig. 1). No neoplastic le-

sions were noted in other organs, including the appendix. Upper gastrointestinal endoscopy and colonoscopy revealed only external compression effects. The aspirated ascitic fluid sample was exudative fluid, containing high concentrations of CA19-9 (11,633 U/ml), carcinoembryonic antigen (2,150 ng/ml), and hyaluronic acid (8,940 ng/ml). Cytological examination of the sample showed a cluster of mucinous atypical cells showing papillary growth, which were positive for periodic acid-Schiff reaction and Alcian blue staining without hyaluronidase digestibility, but were negative for calretinin stain. Culture of the fluid sample showed no bacterial growth. Endoscopic retrograde pancreatography revealed a single cystic lesion measuring 20 mm in diameter that communicated with the main pancreatic duct, with intracystic defects suspected to be a mural nodule measuring 7 mm in diameter and mucous plaques, at the pancreatic tail (fig. 2). The main pancreatic duct was slightly dilated from the head to the body of the pancreas. No contrast image was obtained for the pancreatic duct upstream from the cystic lesion. Based on the clinical features and laboratory and imaging data, a provisional diagnosis of PMP accompanied by IPMN of the pancreas was made. At exploratory laparotomy, abundant yellowish ascitic fluid and multiple gelatinous nodules of various sizes were identified within the peritoneal cavity. Gross examination showed no mass in the gastrointestinal tract or appendix. It was difficult to prove that the IPMN of the pancreas had caused PMP based on inspection and palpation of the pancreas during operation. As complete resection of the peritoneal and omental implants was impossible, part of the thickened omentum, 8 cm in diameter, was excised for pathological examination. During surgery, IHCP was performed using 300 mg of cisplatin, 200 mg of etoposide, and 20 mg of mitomycin C for 60 min under hyperthermic conditions (42°C). Microscopically, the specimen obtained from the omentum was composed of fibrous tissue with abundant

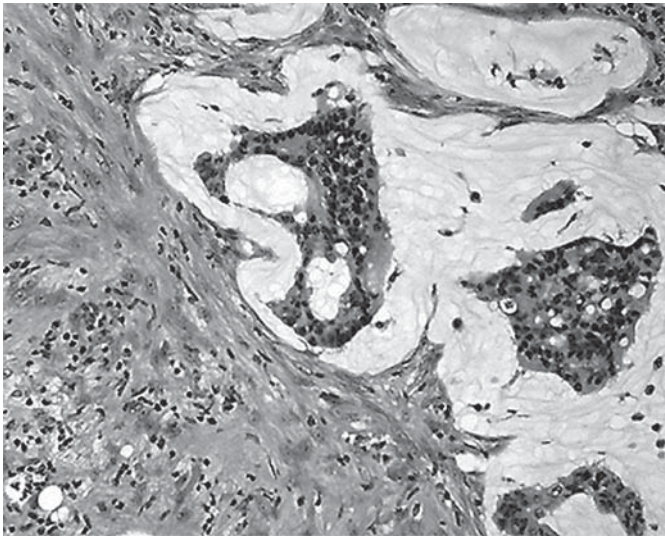


Fig. 3. Microscopic examination of the omentum showing mucinous adenocarcinoma in abundant pools of mucoid material (haematoxylin and eosin staining, $\times 40$).

pools of mucoid material, in which mucinous cells showed nuclear pleomorphism and occasionally formed tubular or papillary projections (fig. 3). These features were consistent with PMP. The patient had an uneventful recovery, and at 26 days after surgery, 100 mg of cisplatin was again administered by intraperitoneal injection through the held catheter. Adhesiotomy was performed for adhesive ileus in June 11, 2002. Subsequently, the patient received 24 courses of postoperative chemotherapy by gemcitabine (1,000 mg/m²/week every 3/4 weeks) from June 2002 to May 2004. Computed tomography showed encapsulated fluid and a large cystic lesion of the pancreas, but no increase in ascites or recurrence of tumour at 24 months after surgery (fig. 4). At the most recent clinical check-up, the patient remains in good general condition with a mildly elevated serum concentration of CA125 (43 U/ml), but operation for IPMN is under consideration because of the progressive enlargement of the lesion in the pancreatic tail.

Discussion

PMP is characterized by massive ascites with dissemination of mucinous adenocarcinoma in the peritoneal cavity [1–3], as was found in our patient. PMP commonly arises from mucinous tumours of the appendix and occasionally from the ovary [1–3]. Interestingly, our patient had IPMN of the pancreas, which was diagnosed by endoscopic retrograde pancreatography and computed tomography that showed typical findings during follow-up, although not histopathologically, while the appendix showed no abnormal findings during exploratory laparotomy. PMP is rarely reported to be associated with mu-

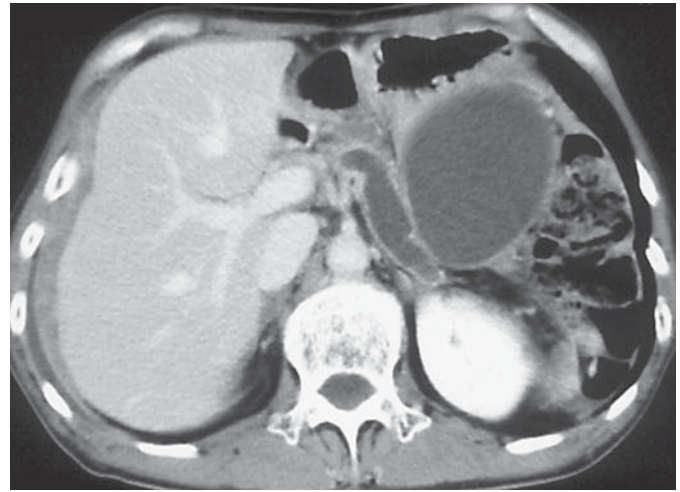

Fig. 4. Follow-up computed tomography showing encapsulated fluid and extensive dilatation of the pancreatic duct, but no sign of progression of pseudomyxoma peritonei.

cinous carcinoma of the pancreas, including mucinous cystadenocarcinoma and IPMN [6–10] (table 1). IPMNs of the pancreas are characterized by cystic dilatation of the main and/or branch pancreatic duct as a result of excessive production and disturbance in the draining of mucin [4, 5]. Overall, IPMNs are associated with favourable prognosis, but approximately 50% of cases are associated with invasive carcinomas [4]. It has been reported that tumour size larger than 30 mm and mural nodule size larger than 5 mm are predictive for the diagnosis of malignant IPMNs [11]. Considering the intracystic mural nodule and the progressive enlargement of the cystic lesion, malignancy cannot be denied in our patient. To date, there is only one report of PMP originating from IPMN of the pancreas, in which PMP possibly was associated with intraoperative leakage of the pancreatic juice [6]. In addition, it has been demonstrated that dissemination of mucinous adenocarcinoma may be caused iatrogenically not only by surgical intervention but also by endosonographically guided fine-needle aspiration biopsy [12, 13]. In our case, IPMN of the pancreas was unknown prior to presentation, and it is possible that PMP was associated with latent rupture or fistula formation of the IPMN into the peritoneal cavity. However, one cannot completely exclude the possible presence of another neoplasm elsewhere as the source of PMP in our case, because it is known that synchronous or metachronous malignancy develops in various organs in IPMN [5].

Table 1. Summary of reported cases of PMP combined with PT

Reference	Age/Sex	PT	Pancreatectomy	Chemotherapy for PMP	Survival
7	89/M	MA	–	–	>7 months
8	57/M	CA	–	–	2 weeks
9	ND/F	MA	ND	ND	2 years
6	49/M	IPMN	+ (partial → total)	SC (5-FU, CBDCA)	>17 months
10	55/F	MCA	+ (distal)	IPC (CDDP)	>4 years
Present case	53/M	IPMN	–	IHCP (CDDP, ETP, MMC) + SC (GEM)	>2 years

PT = Pancreatic tumour; PMP = pseudomyxoma peritonei; ND = not described; MA = mucinous adenocarcinoma; CA = colloid adenocarcinoma; IPMN = intraductal papillary mucinous neoplasm; MCA = mucinous cystadenocarcinoma; SC = systemic chemotherapy; 5-FU = 5-fluorouracil; CBDCA = carboplatin; IPC = intra-peritoneal chemotherapy; CDDP = cisplatin; IHCP = intraperitoneal hyperthermic chemoperfusion; ETP = etoposide; MMC = mitomycin C; GEM = gemcitabine.

Several treatment modalities including surgery, radiotherapy, and chemotherapy have been utilized in the management of PMP with varying degrees of success. Modern treatments include peritonectomy and IHCP [1, 2, 14]. A recent report by Sugarbaker [15] has suggested that an aggressive approach consisting of ‘maximal’ surgical debulking and ‘maximal’ regional chemotherapy has an impact on the outcome of the disease, but the optimal management of the disease remains controversial. In our case, extensive cytoreductive surgery was not performed for two reasons; difficulty in removal of all visible disease and attempt to ensure a good postoperative quality of life. PMP usually shows no lymphatic or haematogenous spread, and intraperitoneal chemotherapy permits delivery of high concentrations of the drug to the peritoneal cavity [2]. In addition, the penetration of the drug into tissue is augmented by heat [16]. Thus, most investigators have suggested the benefit of IHCP [1, 2, 14, 16]. Our patient received IHCP with the use of cisplatin, etoposide,

and mitomycin C, followed by systemic chemotherapy with gemcitabine, which has been used also for the treatment of pancreatic cancer peritonitis and explored for a wider role [17, 18]. The patient has been doing well with no evidences of progression of PMP or serious side effects for 2 years. Given these results, this combined chemotherapeutic regimen seems to be effective for treatment of PMP and improves quality of life. On the other hand, the antitumour treatment had no effects on IPMN of the pancreas. In gastrointestinal malignancies with carcinomatous peritonitis, it is known that the effect of local and systemic chemotherapy often differs between the primary site and malignant ascites [19].

In conclusion, we reported an unusual case of PMP accompanied by IPMN of the pancreas, in which PMP was successfully managed by combination chemotherapy with hyperthermia. Randomised clinical trials are needed to evaluate the true role of IHCP followed by systemic chemotherapy in PMP and associated malignancy.

References

- van Ruth S, Acherman YI, van de Vijver MJ, Hart AA, Verwaal VJ, Zoetmulder FA: Pseudomyxoma peritonei: A review of 62 cases. *Eur J Surg Oncol* 2003;29:682–688.
- Galani E, Marx GM, Steer CB, Culora G, Harper PG: Pseudomyxoma peritonei: The ‘controversial’ disease. *Int J Gynecol Cancer* 2003;13:413–418.
- Weaver CH: Mucocele of the appendix with pseudomucinous degeneration. *Am J Surg* 1937;36:523–526.
- D’Angelica M, Brennan MF, Suriawinata AA, Klimstra D, Conlon KC: Intraductal papillary mucinous neoplasms of the pancreas: An analysis of clinicopathologic features and outcome. *Ann Surg* 2004;239:400–408.
- Tanaka M: Intraductal papillary mucinous neoplasm of the pancreas: Diagnosis and treatment. *Pancreas* 2004;28:282–288.
- Zanelli M, Casadei R, Santini D, Gallo C, Verdirame F, La Donna M, Marrano D: Pseudomyxoma peritonei associated with intraductal papillary-mucinous neoplasm of the pancreas. *Pancreas* 1998;17:100–102.
- Gustafson KD, Karnaze GC, Hattery RR, Scheithauer BW: Pseudomyxoma peritonei associated with mucinous adenocarcinoma of the pancreas: CT findings and CT-guided biopsy. *J Comput Assist Tomogr* 1984;8:335–338.

- 8 Chejfec G, Rieker WJ, Jablknow VR, Gould VE: Pseudomyxoma peritonei associated with colloid carcinoma of the pancreas. *Gastroenterology* 1986;90:202–205.
- 9 Shen DH, Ng TY, Khoo US, Xue WC, Cheung AN: Pseudomyxoma peritonei – A heterogeneous disease. *Int J Gynaecol Obstet* 1998;62:173–182.
- 10 Mitsuhashi T, Murata N, Sobajima J, Okada N, Suzuki T, Ishida H, Hashimoto D, Miura I, Itoyama S: A case of pseudomyxoma peritonei with a pancreatic cancer treated by the intraperitoneal administration of cisplatin (in Japanese). *Gan To Kagaku Ryoho* 2001;28:1670–1673.
- 11 Kawai M, Uchiyama K, Tani M, Onishi H, Kinoshita H, Ueno M, Hama T, Yamaue H: Clinicopathological features of malignant intraductal papillary mucinous tumors of the pancreas: The differential diagnosis from benign entities. *Arch Surg* 2004;139:188–192.
- 12 Yasuda H, Takada T, Amano H, Yoshida M: Surgery for mucin-producing pancreatic tumor. *Hepatogastroenterology* 1998;45:2009–2015.
- 13 Hirooka Y, Goto H, Itoh A, Hashimoto S, Niwa K, Ishikawa H, Okada N, Itoh T, Kawashima H: Case of intraductal papillary mucinous tumor in which endosonography-guided fine-needle aspiration biopsy caused dissemination. *J Gastroenterol Hepatol* 2003;18:1323–1324.
- 14 Deraco M, Baratti D, Inglese MG, Allaria B, Andreola S, Gavazzi C, Kusamura S: Peritonectomy and intraperitoneal hyperthermic perfusion (IPHP): A strategy that has confirmed its efficacy in patients with pseudomyxoma peritonei. *Ann Surg Oncol* 2004;11:393–398.
- 15 Sugarbaker PH: Cytoreductive surgery and peri-operative intraperitoneal chemotherapy as a curative approach to pseudomyxoma peritonei syndrome. *Eur J Surg Oncol* 2001;27:239–243.
- 16 Sugarbaker PH, Ronnett BM, Archer A, Averbach AM, Bland R, Chang D, Dalton RR, Ettinghausen SE, Jacquet P, Jelinek J, Koslowe P, Kurman RJ, Shmookler B, Stephens AD, Steves MA, Stuart OA, White S, Zahn CM, Zoetmulder FA: Pseudomyxoma peritonei syndrome. *Adv Surg* 1996;30:233–280.
- 17 Horiki N, Maruyama M, Fujita Y, Suzuki Y, Tanaka T, Shimomura M, Tanigawa K, Sasaki H, Fujiwara M, Suzuki K, Imoto I, Adachi Y: Gemcitabine treatment of pancreatic cancer peritonitis (in Japanese). *Nippon Shokakibyō Gakkai Zasshi* 2003;100:73–78.
- 18 Li D, Xie K, Wolff R, Abbruzzese JL: Pancreatic cancer. *Lancet* 2004;363:1049–1057.
- 19 Koda K, Nakazawa O, Terada S, Kure T, Morita K, Hirayama M, Fukushi A, Terui T, Yoshizaki N, Takahashi H: Intraperitoneal (IP) administration of cisplatin in combination with systemic chemotherapy in patients with malignant ascites of gastrointestinal cancer: Clinical evaluation and pharmacokinetics (in Japanese). *Gan No Rinsho* 1988;34:191–195.