

Surgical Treatment for Liver Cancer

Current Issues

Masaru Miyazaki Fumio Kimura Hiroaki Shimizu Hiroyuki Yoshidome
Masayuki Ohtsuka Atushi Kato Hideyuki Yoshitomi Satoshi Nozawa
Katsunori Furukawa Dan Takeuchi Kousuke Suda Isaku Yoshioka
Noboru Mituhashi

Department of General Surgery, Graduate School of Medicine, Chiba University, Chiba, Japan

Key Words

Liver cancer · Hepatocellular carcinoma · Hepatectomy ·
Portal vein embolization · Hepatic resection

Abstract

Surgical treatment of hepatocellular carcinoma (HCC) has developed remarkable for several reasons. The surgical mortality rates of patients with HCC after hepatectomy have decreased due to appropriate criteria for surgery, refined surgical techniques and improvement in the pre- and post-operative management. In preoperative management, refinements in liver function tests and strategies for esophageal varices, and the induction of preoperative portal vein embolization have contributed favorably to the outcome after hepatectomy for HCC. Furthermore, hepatectomy has been technically refined by various vascular control methods and liver transection devices based on the realization that surgical anatomical information also plays a major role in improving surgical outcome. Also concomitant splenectomy with hepatectomy might extend the criteria for surgery in HCC patients with hypersplenism. Therefore, hepatectomy is a safe therapeutic approach that could bring about a favorable outcome in patients with HCC. Nowadays transplantation is one of the therapeutic options for HCC pa-

tients, even in Japan. Herein the surgical treatment of HCC in Japan is reviewed and current issues in the surgical treatment of HCC are discussed.

Copyright © 2007 S. Karger AG, Basel

Introduction

Surgical treatment of hepatocellular carcinoma (HCC) has remarkably improved for several reasons. The surgical mortality rates of HCC patients have decreased after hepatectomy due to the appropriate criteria for surgery, refined surgical techniques, and improvement in pre- and postoperative management. Therefore, hepatectomy has become a safe therapeutic approach that could bring about a favorable outcome for HCC patients. Herein, the surgical treatment of HCC in Japan is reviewed, and current issues in the surgical treatment of HCC are described.

Preoperative Management

Evaluation of Liver Function

In Japan 90% of HCC patients have chronic liver dysfunction due to hepatitis B or C virus infection [1]. There-

fore, preoperative evaluation of liver function is very important to decide the surgical indication in HCC patients and to perform surgery safely. Several hepatic function tests have been developed and were applied to patients in the 1980s and 1990s. At present the most frequently used assessments are the Child-Pugh classification and indocyanine green (ICG) test. Other tests, such as blood coagulation factors (partial thromboplastin time, hepaplastin test, etc.), galactose elimination capacity, and asialoscintigraphy, are also useful as additional functional tests. However, the ICG test cannot evaluate liver function correctly in patients with obstructive jaundice. In such cases, the galactose elimination capacity and blood coagulation factors could be useful parameters. Obstructive jaundice is seldom found in HCC patients, but is usually encountered in patients with intrahepatic cholangiocarcinoma because it often involves the hilar bile duct and induces obstructive jaundice.

Recently, patients with HCC and liver cirrhosis have been classified according to newly proposed score systems such as the Cancer of the Liver Italian Program (CLIP) score [2] and Japan Integrated Staging (JIP) score [3]. These scoring systems are related to both tumor stage and liver function. Although the CLIP scoring system has been well validated by many authors [4–6] in terms of its prognostic value in HCC patients, this scoring system has some problems and limitations when applied to patients with early-stage HCC. Therefore, a new staging system based on the Liver Cancer Study Group of Japan, the JIS score has been proposed in Japan [3]. This staging system combined the Child-Pugh grade and TNM staging. Further reevaluation of these staging systems must be done.

Preoperative Portal Vein Embolization

Portal vein embolization, developed by Makuuchi et al. [7] and Kinoshita et al. [8], has also been applied not only to patients with obstructive jaundice but also to cirrhotic patients with HCC. Kinoshita et al. [8] and Abdalla et al. [9] have shown the usefulness of portal vein embolization in patients with liver cirrhosis undergoing major hepatectomy. Embolization could be indicated in patients undergoing major hepatectomy when the estimated liver volume after hepatectomy is not enough to tolerate surgery. A recent report [10] has shown that sequential transarterial chemoembolization and portal vein embolization before surgery increase the rate of hypertrophy of the future remnant liver volume and lead to a higher rate of complete tumor necrosis associated with a longer recurrence-free survival. Furthermore, preoperative portal vein embolization might bring about the

benefit of avoiding intraportal venous tumor spreading into the liver during operation. Portal vein embolization before hepatectomy for HCC might have beneficial effects not only on liver functional capacity, but also on oncological control.

Splenectomy

Most patients with HCC have a cirrhotic liver, and some of them have concomitant hypersplenism and portal hypertension. It is still controversial whether HCC patients with thrombocytopenia should undergo surgical resection or not if liver function is tolerable enough for them to have hepatectomy. Splenectomy has been advocated for patients with HCC and thrombocytopenia prior to hepatectomy or synchronously. Sugawara et al. [11] reported that splenectomy can increase the safety of hepatectomy in selected patients with HCC by reducing both the likelihood of bleeding complications and bilirubin overload. Chen et al. [12] also reported that simultaneous hepatectomy and splenectomy is associated with an improved 5-year tumor-free survival in patients with HCC and hypersplenism. Therefore, patients with HCC and hypersplenism should not be considered irresectable only due to thrombocytopenia.

Strategy for Esophageal Varices

If the HCC patient has esophageal varices that could rupture, preoperative endoscopic treatments such as variceal ligation and sclerotherapy should be performed to avoid postoperative bleeding after hepatectomy [13, 14]. Partial splenic embolization has also been done preoperatively for patients with HCC, especially when accompanied by thrombocytopenia [15, 16]. During hepatic resection for HCC, the Hassab operation and splenectomy might be performed concomitantly aiming to control esophageal varices and thrombocytopenia more effectively [17, 18].

Operative Procedures

Surgical resection for HCC should be done by anatomical hepatectomy according to the inflowing vessels at the sub-segment level such as segments II, V, etc., according to Couinaud's classification. Systemized hepatectomy with Glisson's pedicle transection at the hepatic hilus has commonly been utilized in hepatectomy for small HCC in cirrhotic patients (fig. 1, 2). Anatomical resection has been considered beneficial for complete segmental resection of the cancer burden and the non-valid

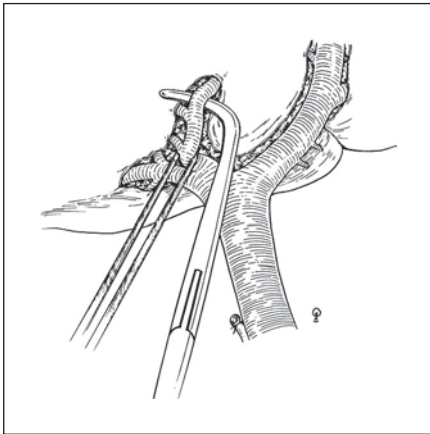


Fig. 1. Segment VIII hepatectomy by systematic Glisson's pedicle transection at the hepatic hilus.

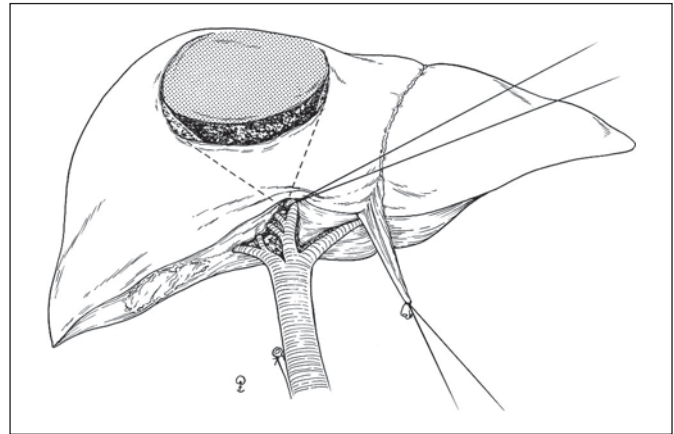


Fig. 2. Segment VIII hepatectomy; parenchymal transection following Glisson's pedicle ligation at the hepatic hilus.

hepatic parenchyma. While during transection of the hepatic parenchyma both Pringle's maneuver and hemivascular clamp have commonly been utilized to reduce intraoperative blood loss, no obvious differences in liver damage, blood loss and operative time have been found between the two vascular control methods [19–22]. Several mechanical devices, such as CUSA, Bipolar electrocautery, Water-Jet, Microwave Coagulator and Tissue Link, etc., have independently been applied during liver parenchymal transection in various institutions. However, there is still no clear evidence showing which of the devices is significantly better than the others [19, 23–26].

In the case of advanced HCC involving the inferior vena cava (IVC) with intravenous tumor thrombus, total hepatic vascular exclusion in the abdominal space should be required for excision of the tumor thrombus from the IVC without massive blood loss [27]. The cirrhotic liver with Child's A and B liver function can tolerate ischemic liver damage over a duration of 30 min. The excision of the tumor thrombus from the IVC commonly takes less than 30 min because HCC seldom directly invades the IVC wall, and therefore reconstruction of the IVC using a graft is usually not required after tumor thrombectomy from the IVC. However, if the tumor thrombus of the IVC extends into the suprarenic IVC or the right atrium, vascular control at the level of intrathoracic IVC or cardiopulmonary bypass should be required for removal of the intravascular tumor thrombus (fig. 3, 4). There have been some case reports with long-term survivors following these aggressive surgical approaches, despite advanced HCC with extensive intravascular tumor throm-

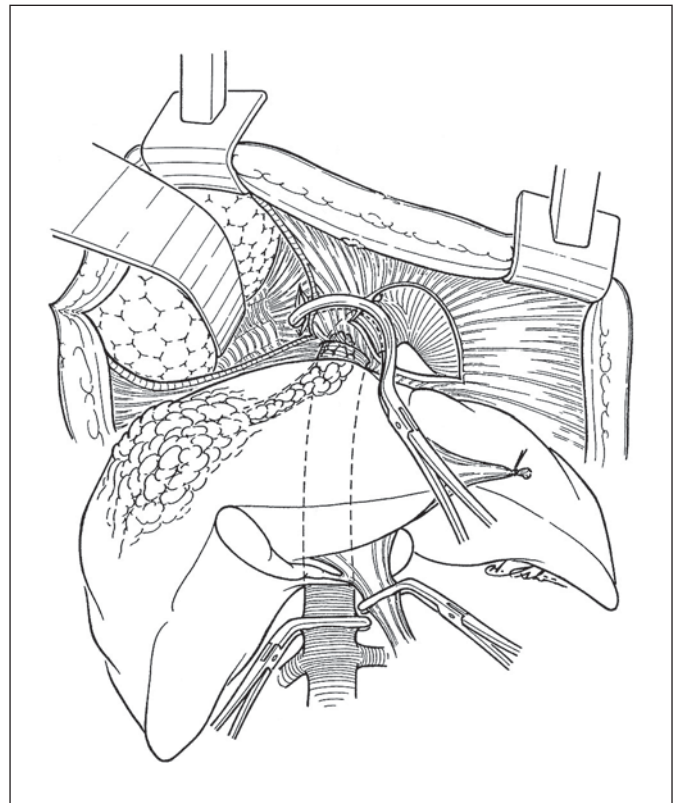


Fig. 3. Total hepatic vascular exclusion for HCC with tumor thrombus extending into the inferior vena cava at the intra-thoracic level.

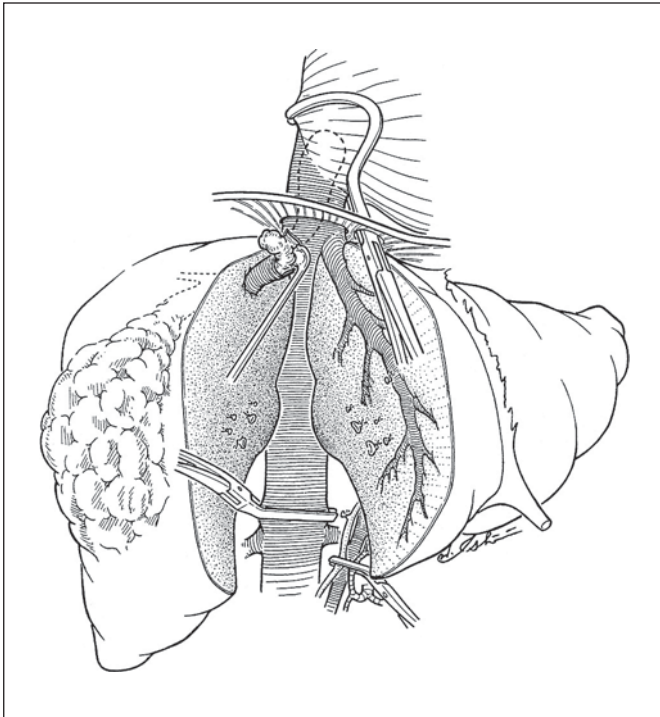


Fig. 4. Hepatectomy for HCC with tumor thrombus extending into the intra-thoracic inferior vena cava under total hepatic vascular exclusion and tumor thrombectomy from the inferior vena cava.

bus [28, 29]. Recently, Sakon et al. [30] reported that interferon may have remarkable effects on irresectable HCC with an intravascular tumor thrombus. At present a prospective clinical trial is in progress to clarify the effect of interferon.

Postoperative Complications and Managements

Many institutions have reported that postoperative liver failure very rarely occurs after hepatectomy [31–35]. The decrease in the incidence of postoperative liver failure might be due to appropriate patient selection by excellent evaluation and well-defined criteria for liver functional reserve, and the improvement in surgical technique. Therefore, hepatic resection for HCC has been done without blood transfusion in most patients. The criteria of Imamura et al. [36], using the ICG test, is very popular and easily available to judge the surgical indication of hepatectomy in cirrhotic patients with HCC. Besides liver failure, there are many other postoperative complications such as pleural effusion, biliary fistula, bi-

loma, abdominal abscess, etc. However, hospital stay after surgery has been shortened without major complications. Therefore, at present the surgical mortality is reported to be less than 1% in most institutions in Japan.

Survival after Operation

Survival after surgical resection has improved remarkably with the recent progress in surgical skills and the use of appropriate indication criteria. Therefore, the surgical mortality rate has decreased to less than 2% as shown by recent reports. However, in 1980 the Liver Cancer Study Group of Japan reported a high surgical mortality rate of 27% in the patients with HCC [37]. The major cause of this high surgical mortality was hepatic failure. Several liver function tests, such as the ICG retention test, asialoscintigraphy, and galactose elimination capacity, could correctly evaluate the preoperative functional reserve of the liver in cirrhotic patients with HCC. Experience with a large number of patients undergoing surgical resection could contribute to the development of appropriate selection criteria in cirrhotic patients by analyzing the surgical outcome retrospectively. The 5-year survival after surgical resection in HCC patients increased from 12 to 55% between 1980 and 2005 in Japan [1]. Recently liver transplantation was performed as a new form of surgical treatment for HCC. In Japan the number of the patients who underwent liver transplantation for HCC greatly increased after 2005 [1]. A follow-up survey of primary liver cancer in Japan in 2005 reported that survival rates in HCC patients were 88, 71, 55, and 29% at 1, 3, 5, and 10 years after surgical resection, respectively [1].

Strategy for Recurrence

One third of the HCC patients who underwent surgical resection have been reported to have recurrence. Transcatheter arterial embolization and local ablation therapy have been utilized mainly for the recurrence of HCC in the liver. However, a small number of the recurrent patients were able to undergo repeat hepatectomy, which resulted in a favorable outcome [38, 39]. Of course liver transplantation has also been performed in strictly selected patients with recurrence of HCC only in the liver [40–42]. Further studies need to be done to clarify the implications of aggressive surgical treatment for recurrent HCC, such as repeat hepatectomy and liver transplantation.

Conclusion

Surgical resection for HCC in the liver has been defined as a safe and effective treatment. Therefore, surgical resection should be considered the first-line therapy for

HCC patients, even cirrhotic patients, and appropriate liver function tests and indication criteria should be used to evaluate whether the patients are able to tolerate surgery.

References

- Ikai I, Arii S, Ichida T, Okita K, Omata M, Kojiro M, Takayasu K, Nakanuma Y, Makuuchi M, Matsuyama Y, Yamaoka Y: Report of the 16th follow-up survey of primary liver cancer. *Hepatol Res* 2006;32:163–172.
- A new prognostic system for hepatocellular carcinoma: a retrospective study of 435 patients: the Cancer of the Liver Italian Program (CLIP) investigators. *Hepatology* 1998;28:751–755.
- Kudo M, Chung H, Osaki Y: Prognostic staining system for hepatocellular carcinoma (CLIP score): its value and limitations, and a proposal for a new staging system, the Japan Integrated Staging Score (JIS score). *J Gastroenterol* 2003;38:207–215.
- Prospective validation of the CLIP score: a new prognostic system for patients with cirrhosis and hepatocellular carcinoma. The Cancer of the Liver Italian Program (CLIP) Investigators. *Hepatology* 2000;31:840–845.
- Levy I, Sherman M; Liver Cancer Study Group of the University of Toronto: Staging of hepatocellular carcinoma: assessment of the CLIP, Okuda, and Child-Pugh staging systems in a cohort of 257 patients in Toronto. *Gut* 2002;50:881–885.
- Llovet JM, Bruix J: Prospective validation of the Cancer of the Liver Italian Program (CLIP) score: a new prognostic system for patients with cirrhosis and hepatocellular carcinoma. *Hepatology* 2000;32:679–680.
- Makuuchi M, Thai BL, Takayasu K, Takayama T, Kosuge T, Gunven P, Yamazaki S, Hasegawa H, Ozaki H: Preoperative portal embolization to increase safety of major hepatectomy for hilar bile duct carcinoma: a preliminary report. *Surgery* 1990;5:521–527.
- Kinoshita H, Sakai K, Hirohashi K, Igawa S, Yamasaki O, Kubo S: Preoperative portal vein embolization for hepatocellular carcinoma. *World J Surg* 1986;10:803–808.
- Abdalla EK, Hicks ME, Vauthey JN: Portal vein embolization: rationale, technique and future prospects. *Br J Surg* 2001;88:165–175.
- Ogata S, Belghiti J, Farges O, Varma D, Sibert A, Vilgrain V: Sequential arterial and portal vein embolizations before right hepatectomy in patients with cirrhosis and hepatocellular carcinoma. *Br J Surg* 2006;93:1091–1098.
- Sugawara Y, Yamamoto J, Shimada K, Yamasaki S, Kosuge T, Takayama T, Makuuchi M: Splenectomy in patients with hepatocellular carcinoma and hypersplenism. *J Am Coll Surg* 2000;190:446–450.
- Chen XP, Huang WZY, Qiu FZ: Use of hepatectomy and splenectomy to treat hepatocellular carcinoma with cirrhotic hypersplenism. *Br J Surg* 2005;92:334–339.
- Amitrano L, Guardascione MA, Bennato R, Manguso F, Balzano A: MELD score and hepatocellular carcinoma identify patients at different risk of short-term mortality among cirrhotics bleeding from esophageal varices. *J Hepatol* 2005;42:820–825.
- Lang BH, Poon RT, Fan ST, Wong J: Outcomes of patients with hepatocellular carcinoma presenting with variceal bleeding. *Am J Gastroenterol* 2004;99:2158–2165.
- Sangro B, Bilbao I, Herrero I, Corella C, Longo J, Beloqui O, Ruiz J, Zozaya JM, Quiroga J, Prieto J: Partial splenic embolization for the treatment of hypersplenism in cirrhosis. *Hepatology* 1993;18:309–314.
- Wu FS, Zhao WH, Liang TB, Ma ZM, Teng LS, Wang M, Zheng SS: Survival factors after resection of small hepatocellular carcinoma. *Hepatobiliary Pancreat Dis Int* 2005;4:379–384.
- Yamamoto S, Sato Y, Takeishi T, Hirano K, Koabayashi T, Watanabe T, Hatakeyama K: Successful surgical treatment for hepatocellular carcinoma and concomitant risky esophageal varices. *Hepatogastroenterology* 2005;52:1083–1086.
- Li H, Hu YL, Wang Y, Zhang DS, Jiang FX: Simultaneous operative treatment of patients with primary liver cancer associated with portal hypertension. *Hepatobiliary Pancreat Dis Int* 2002;1:92–93.
- Lesurtel M, Selzner M, Petrowsky H, McCormack L, Clavien PA: How should transection of the liver be performed? A prospective randomized study in 100 consecutive patients: comparing four different transection strategies. *Ann Surg* 2005;242:814–823.
- Chau GY, Lui WY, King KL, Wu CW: Evaluation of effect of hemihepatic vascular occlusion and the Pringle maneuver during hepatic resection for patients with hepatocellular carcinoma and impaired liver function. *World J Surg* 2005;29:1374–1383.
- Dixon E, Vollmer CM Jr, Bathe OF, Sutherland F: Vascular occlusion to decrease blood loss during hepatic resection. *Am J Surg* 2005;190:75–86.
- Figueras J, Liado L, Ruiz D, Ramos E, Busquets J, Rafecas A, Torras J, Fabregat J: Complete versus selective portal triad clamping for minor liver resections: a prospective randomized trial. *Ann Surg* 2005;241:582–590.
- Nascimento M, Abourjeily N, Ghosh A, Zhang WW, Matlashewski G: Heterologous expression of a mammalian protein tyrosine phosphatase gene in *Leishmania*: effect on differentiation. *Hepatogastroenterology* 2003;50:1517–1520.
- Rau HG, Buttler ER, Baretton G, Schardey HM, Schildberg FW: Jet-cutting supported by high frequency current: new technique for hepatic surgery. *World J Surg* 1997;21:254–260.
- Rau HG, Schardey HM, Buttler E, Reuter C, Cohnert TU, Schildberg FW: A comparison of different techniques for liver resection: blunt dissection, ultrasonic aspirator and jet-cutter. *Eur J Surg Oncol* 1995;21:183–187.
- Saiura A, Yamamoto J, Koga R, Sakamoto Y, Kokudo N, Seki M, Yamaguchi T, Yamaguchi T, Muto T, Makuuchi M: Usefulness of LigaSure for liver resection: analysis by randomized clinical trial. *Am J Surg* 2006;192:41–45.
- Miyazaki M, Ito H, Nakagawa K, Ambiru S, Simizu H, Okuno A, Nukui Y, Yoshitomi H, Kusashio K, Furuya S, Nakajima N: Aggressive surgical resection for hepatic metastases involving the inferior vena cava. *Am J Surg* 1999;177:294–298.
- Kashima Y, Miyazaki M, Ito H, Kaiho T, Nakagawa K, Ambiru S, Shimizu H, Futuya S, Nakajima N: Effective hepatic artery chemoembolization for advanced hepatocellular carcinoma with extensive tumour thrombus through the hepatic vein. *J Gastroenterol Hepatol* 1999;14:922–927.
- Miyazaki M, Ito H, Nakagawa K, Shimizu H, Yoshidome H, Shimizu Y, Ohtuska M, Togawa A, Kimura F: An approach to intrapericardial inferior vena cava through the abdominal cavity, without median sternotomy, for total hepatic vascular exclusion. *Hepatogastroenterology* 2001;48:1443–1446.

- 30 Sakon M, Nagano H, Dono K, Nakamori S, Umeshita K, Yamada A, Kawata S, Imai Y, Lijima S, Monden M: Combined intraarterial 5-fluorouracil and subcutaneous interferon-alpha therapy for advanced hepatocellular carcinoma with tumor thrombi in the major portal branches. *Cancer* 2002;94:435-442.
- 31 Cucchetti A, Ercolani G, Cescon M, Ravaoli M, Zanello M, Del Gaudio M, Lauro A, Vivarelli M, Luca Grazi G, Pinna AD: Recovery from liver failure after hepatectomy for hepatocellular carcinoma in cirrhosis: meaning of the model for end-stage liver disease. *J Am Coll Surg* 2006;203:670-676.
- 32 Schroeder RA, Marroquin CE, Bute BP, Khuri S, Henderson WG, Kuo PC: Predictive indices of morbidity and mortality after liver resection. *Ann Surg* 2006;243:373-379.
- 33 Blazan S, Belghiti J, Farges O, Ogata S, Sauvanet A, Delefosse D, Durand F: The '50-50 criteria' on postoperative day 5: an accurate predictor of liver failure and death after hepatectomy. *Ann Surg* 2005;242:824-829.
- 34 Maeda Y, Nishida M, Takao T, Tamesa T, Tangoku A, Oka M: Risk factors for postoperative liver failure after hepatectomy for hepatocellular carcinoma. *Hepatogastroenterology* 2004;51:1792-1796.
- 35 Fan ST, Lai EC, Lo CM, Ng IO, Wong J: Hospital mortality of major hepatectomy for hepatocellular carcinoma associated with cirrhosis. *Arch Surg* 1995;130:198-203.
- 36 Imamura H, Sano K, Sugawara Y, Kokudo N, Makuuchi M: Assessment of hepatic reserve for indication of hepatic resection: decision tree incorporating indocyanine green test. *J Hepatobiliary Pancreat Surg* 2005;12:16-22.
- 37 Okuda K; the Liver Cancer Study Group of Japan: Primary liver cancers in Japan. *Cancer* 1980;45:2663-2669.
- 38 Shimada M, Takenaka K, Taguchi K, Fujiwara Y, Gion T, Kajiyama K, Maeda T, Shirabe K, Yanaga K, Sugimachi K: Prognostic factors after repeat hepatectomy for recurrent hepatocellular carcinoma. *Ann Surg* 1998;227:80-85.
- 39 Nagasue N, Kohno H, Hayashi T, Uchida M, Ono T, Yukaya H, Yamanoi A: Repeat hepatectomy for recurrent hepatocellular carcinoma. *Br J Surg* 1996;83:127-131.
- 40 Prak JW, Lee KW, Kim SJ, Choi SH, Heo JS, Kwon CH, Kim DJ, Han YS, Lee SK, Joh JW: Outcome of patients with recurrent hepatocellular carcinoma in liver transplantation. *Transplant Proc* 2006;38:2121-2122.
- 41 Grasso A, Stigliano R, Morisco F, Martines H, Quaglia A, Dhillon AP, Patch D, Davidson BR, Rollets K, Burroughs AK: Liver transplantation and recurrent hepatocellular carcinoma: predictive value of nodule size in a retrospective and explant study. *Transplantation* 2006;81:1532-1541.
- 42 Yokoi H, Isaji S, Yamagiwa K, Tabata M, Nemoto A, Sakurai H, Usui M, Uemoto S: The role of living-donor liver transplantation in surgical treatment for hepatocellular carcinoma. *J Hepatobiliary Pancreat Surg* 2006;13:123-130.