

.....

Painting after Right-Hemisphere Stroke – Case Studies of Professional Artists

H. Bänzner, M.G. Hennerici

Department of Neurology, University of Heidelberg, Universitätsklinikum Mannheim,
Mannheim, Germany

Abstract

Changes in the style of professional artists as an immediate consequence of cerebrovascular disease are an intriguing phenomenon for the neuroscientist. While left-hemisphere damage is commonly provoking alterations in verbal production and comprehension, right-hemisphere stroke often leads to left-sided visuospatial neglect. We present a case series of 13 professional artists with right-hemisphere stroke and compare examples of their post-stroke artwork with their prestroke artwork.

Copyright © 2007 S. Karger AG, Basel

Cerebrovascular disease and its related medical problems are very common. Brain lesions caused by stroke may result in devastating disability for the stroke victim. Through the continuously improving neurophysiological and neurosonological techniques and through the development of high-resolution neuroimaging technologies precise localization of lesions has become possible. Hence, pathophysiological mechanisms leading to stroke are better understood. Recent developments in neuropsychology have revealed certain regularities in the consequences of strokes depending on lesion extent and localization. Therefore, our knowledge is growing regarding the effects of stroke in the majority of patients. However, facing the specialized individual and highly developed skills of professional artists, and, moreover, lacking a reasonably large patient collective, only few authors have aimed at analyzing the consequences of stroke in professional visual artists systematically. On the other hand, some very interesting case reports have been produced, going back to the early 20th century. A seminal article including the cases of four German professional artists with right-hemisphere lesions has been published in 1974 by

Prof. Richard Jung, a clinical neurologist and researcher in neurophysiology, of Freiburg, Germany. In his paper he reported the cases of Anton Räderscheidt, Lovis Corinth, Otto Dix, and Johannes Thiel [Jung, 1974].

By reviewing the literature and by adding several additional cases, totaling a number of 13 professional visual artists, we will try to comment on common features of right-hemisphere damage with an emphasis on artistic production. We are well aware of the limitations of our effort, since the freedom of art rarely follows simplistic rules. Certainly artists and art historians will not always share the neurological point of view. Therefore we are obliged to interpret our observations with care.

(1) Anton Räderscheidt

Anton Räderscheidt (October 11, 1892 to March 8, 1970) started his artistic career in his birth town of Cologne. His portraits and figure paintings were shown in the famous ‘Neue Sachlichkeit’ exhibition in Mannheim in 1925. He was a protagonist of the ‘Magischer Realismus’ (magic realism), where persons and their surroundings were painted close to photographic art and the emotional content was reduced to a minimum as opposed to the contemporary expressionistic painters. His art being declared ‘degenerate’ by the Nazis, he emigrated from Germany in 1935, lived in Switzerland, England and France until 1949, when he returned to Cologne with his second wife, Gisèle. His artistic style changed after 1950, now inspired by abstract expressionism. On September 24, 1967, shortly before a large retrospective in Cologne, Räderscheidt suffered a stroke with severe visual disturbances and a mild left hemisindrome. He had a homonymous hemianopsia to the left with a left-sided hemineglect, a disturbance of spatial orientation and an initially severe prosopagnosia. The problem of face recognition was so severe that he was unable to recognize even close relatives. This latter problem persisted over weeks [Jung, 1974; Herzog, 1991]. Beginning in December 1967 and continuing until June 1969, Räderscheidt painted an enormously large series of more than 60 self-portraits with the intention to compensate for the severe left-sided hemineglect. In Jung’s 1974 paper, the improvement of his neglect was illustrated using five of these self-portraits. A set of four consecutive self-portraits [fig. 8b and 9a–c of Jung, 1974] were later repeatedly published [Gardner, 1977; Butter, 2004]. Räderscheidt is cited with the following remark concerning his stroke: ‘Using all of my willpower, I intended to force my eyes to see correctly again. . . . A stroke has taken me away from the scene of life; offstage the play is going on with me. I am no longer the director of this play. I have to take care, not to miss my entrance in the play. My requisites obey to tricks only. Moreover, I am missing my loud colours. . . . The reproduction of my surroundings is a damned difficult thing. Nothing is staying in its place, nothing is keeping the shape. Perhaps I will be able to get hold of a



Fig. 1 a, b. Anton Räderscheidt's poststroke paintings display ecstatic scenes, often depicting couples in close personal contact. Persons are grossly deformed, the artist using brighter colors and a larger variety of colors compared to his prestroke art. A moderate left-sided hemineglect can be noted (copyright VG Bild-Kunst, Bonn, 2007).

credible shape now if I can use this permanent motion. . . . In the past it felt like hunting [shape], now it feels more like catching a trout in moving water using bare hands. . . . Painting is like taming beasts of prey' [Richter, 1972; Herzog, 1991]. Neurological examination was not controlled until his death in March 1970; however, Jung assumes that his hemianopia was unchanged and that the painter learned to compensate for his neglect [Jung, 1974]. The change in artistic style in his late paintings displaying couples or nudes was discussed already by Jung who noticed a stronger affective relationship. Räderscheidt's son Pascal, who runs a remarkable web site (www.raederscheidt.com) presenting biographical data and a large collection of his father's artwork, says that his father referred to these paintings as 'Böse Bilder' (nasty paintings). These tempera paintings on cardboard, all in the same format, have been produced between June 1968 and August 1969. As to artistic expression, a total revolution occurred: compared to his earlier grouped figures and couples which lack any emotional content and avoid any personal contact, his poststroke paintings are overloaded with wild colorful brushstrokes, display ecstatic scenes, often depicting couples in close personal contact (fig. 1). Persons, who had previously been painted in a very realistic manner, are widely deformed, the artist uses brighter colors, and color variety is larger. His biographer Herzog [1991] describes the structure of the 'Böse Bilder' as 'acompository', and says, that the physiognomy of the figures is

‘disfigured beyond recognition’. After June 1968, Räderscheidt’s condition declined, although he still used to paint on every day. Again hospitalized between May and June 1969, his declining physical strength forced the painter to use smaller formats. Räderscheidt commented on his poststroke work in the last words of his diary as follows: ‘After a 60 year long lasting fight with the material (form and colour), the material seems to have prevailed. My paintings become interesting to me, I start to enjoy them as a spectator’ [Herzog, 1991].

(2) *Otto Dix*

Otto Dix (December 2, 1891 to July 25, 1969) was born in Untermdorf near Gera, studied in Düsseldorf and Dresden and became Professor of Arts of the Dresden Academy of Arts in 1927. He was well known in his early years for his naturalistic-veristic style, was painting large series of war scenes after being a soldier in the First World War. His portraits in the 1920s were often overcharacterized and displayed ugly human figures close to caricature. His paintings were classified as ‘degenerate’ and he was forced to leave the Academy of Arts in 1933. He moved to the Bodensee, where he stayed for more than 30 years until his death in 1969 [Schubert, 1980].

On November 13, 1967, Dix suffered a right-hemisphere stroke with left-sided hemiparesis, left hemineglect, partial hemianopia and mild spatioconstructive disturbances. Moreover, a reduced proprioception and apraxia of his left arm were noted by his treating neurologist, Prof. Baumgartner of Zürich. In the first 3 days following the stroke, Dix was unable to draw at all. On day 4 after the onset of symptoms, he was able to draw a simple and small sketch of a tree, with a unilateral shadowing giving the tree a plastic appearance. The left part of the paper was left free indicating his neglect. One week later, the neglect seemed widely compensated in a second sketch of a tree (both sketches are documented in Dix’ patient chart in Zürich University Hospital and are reproduced by Jung [1974]). However, we cannot support Jung’s view of an unchanged drawing style. His drawing was altered noticeably at least in his last self-portraits. The self-portrait with black collar (1968), small self-portrait (1968), self-portrait with a hand (1968) and self-portrait as a skull (1968) all share a missing resemblance with the painter. This is substantially different from the self-portraits Dix painted in 1957 (fig. 2b), 1964 (fig. 2c), and 1967 whose similitude is very close to the photographs showing Dix at the respective dates (fig. 2a). The self-portrait with black collar bears a certain resemblance to Dix, but spatial relations and facial structures are irritating, with his closed right eye seemingly protruded (fig. 2d). The painter’s face appears to be supported on the left side of the portrait by a frame-like band seemingly preventing the painter’s head from falling forward. The small self-portrait has much of a caricature (fig. 2e), and the self-portrait with a hand shows the painter’s hand holding the




Fig. 2. ‘Otto Dix’ drawing style was altered noticeably in his last self-portraits. Self-portrait with black collar (1968, *d*), small self-portrait (1968, *e*), self-portrait with a hand (1968, *f*) and self-portrait as a skull (1968, not shown) all share the absence of a resemblance to the painter. This is substantially different from the self-portraits Dix painted in 1957 (*b*), 1964 (*c*), and 1967 whose similitude is very close to the photographs showing Dix at the respective dates (*a*) (copyright VG Bild-Kunst, Bonn, 2007).

pencil in the forefront of the drawing covering most parts of the lower face (fig. 2f). On this right hand we count more than five fingers – the same observation can be made with certitude in his last large self-portrait with Marcella (1969), where Dix holds the little girl with both hands. On his right hand six fingers can be differentiated. Dix continued to paint until his death, working mostly on lithographs. He died of a second stroke on July 25, 1969 in Singen. Hans Kinkel, in his preface to Florian Karsch’s catalogue of Dix’ graphic art describes the painter’s reaction to the stroke and the series of late self-portraits as an ‘obsessingly

urgent self-inquiry'. 'Lines became seismographic tracks; the structure was decomposed into flickering hieroglyphs. Outer appearance was replaced by inner similarity' [Kinkel, 1970].

(3) *Johannes Thiel*

Johannes Thiel (September 11, 1889 to July 31, 1962) travelled in Europe after studies at the Academies of Art in Munich and Stuttgart. He lived in Kirchzarten near Freiburg, producing landscape and figure paintings and book illustrations. His best artwork, according to Jung [1974], was his water color landscapes, where Thiel reached perfection in his 6th and 7th decade of life. He suffered two strokes with left-sided hemiparesis in 1959 (facial paresis on the left and mild weakness of the left hand with complete recovery) and 1960 (with a permanent left hand weakness) but recovered fairly well and was enormously productive until a third stroke in 1962 set an end to his life. Except for a portrait sketch done in the days following his first stroke, Jung is unable to notice any change in style or signs of neglect. Jung examined Thiel after his third and subsequently fatal stroke and described a left-sided hemiplegia and hemianopia.

(4) *Lovis Corinth*

Lovis Corinth (July 21, 1858 to July 17, 1925), who certainly had the most interesting patient history of this case series, is the subject of a separate chapter by Bänzner and Hennerici (pp. 30–43).

(5) *Wolfgang Aichinger-Kassek*

Wolfgang Aichinger-Kassek is an Austrian artist who suffered a right-hemisphere stroke on the basis of arterioarterial embolism from a severe carotid stenosis in 1995 [Aichinger-Kassek, 1997]. When he recovered slowly from his stroke he noticed that he was unable to continue working on his sculptures which he had constructed using heavy materials, cut from metal-welded iron. As a reaction to this drawback, he produced a series of 'neurological folios' comprising 30 colored graphics (fig. 3). His daughter, a consultant in neurology, writes in the preface to this collection: 'As soon as the acute stage of the apoplectic fit was over, it gave way to thoughts about the how of his future artistic career. They all ended in the question whether creative activity would still be possible. For many long months, the phases of depression and despair seemed to hold the upper hand. The paralysis of thought and inspiration outweighed all other problems. The artist's dependency on his ideas obliged [him] to assume the role of waiting in uncertainty of his fate. But then, from one day to the next, feelings and inspirations forced their way to the surface. It became possible to represent pictorially the phases of depression, fear, of incursions into his own body, the hospital



Fig. 3 a, b. Wolfgang Aichinger-Kassek, an Austrian artist suffered a right-hemisphere stroke in 1995. As a reaction, he produced a series of ‘neurological folios’. According to the artist’s daughter, they represent ‘pictorially the phases of depression, fear, of incursions into his own body, the hospital environment’ (private collection).

environment. Most of the works in this cycle were created within a few days. The person W.A. now sees prospects for his future once again.’ Aichinger-Kassek himself comments on his stroke as follows: ‘Apoplexy – that’s a stroke of lightning in life’s thunderstorm! It attacks you! And fells you like a blossoming tree. The stroke is the insidiousness of an unexpected menace. It’s danger and warning. The stricken [sic!] one is defeated by a depressive attack while his life is passing before his eyes like a trashy movie. Apoplexy – that’s also a determination of life-positions consisting in bygone past and uncertain future. At all, uncertainty is a serious component of insidiousness.’

(6) Federico Fellini

The case of the famous Italian movie director and skilled painter and cartoonist Federico Fellini (1920–1993) was reported extensively in 1998 [Cantagallo and Della Sala, 1998; Chatterjee, 2004]. The authors followed the artist for 2 months after a CT-documented right temporoparietal ischemic stroke leaving the artist with a severe sensorimotor hemisyndrome and left inferior quadrantanopia. Fellini was examined in detail for his left visuomotor hemineglect

syndrome, including neglect dyslexia as well as some evidence of implicit processing of the neglected parts of the stimuli. The artist was aware of his motor and attentional deficits; however, he was unable to functionally compensate for them. The documents of visuomotor neuropsychological testing are reproduced in the paper and demonstrate besides the pure neuropsychological deficit a remarkable introspective analysis of the artist's own situation including some quite ironical and sometimes provocative though charming personalized performances. Federico Fellini is presented in detail in the chapter by Dieguez et al., pp. 44–74.

(7) *Reynold Brown*

Reynold Brown (1917–1991) got his first art education in the Alhambra High School in California. The following information was obtained through the web site designed and maintained by his son Franz (www.geocities.com/chapulinas). He illustrated and drew a comic strip, did illustrations for service manuals, several magazines and pocket books. In the 1950s Brown decided to go back to free-lance illustration, and took a teaching position at the Art Center College of Design. There, he would teach figure and head drawing for 26 years. At that time, he started a series of movie posters for the large movie companies and of record jacket covers. From the 1970s on Brown concentrated on fine arts painting with western themes as his preferred subject, where he succeeded and sold about 250 oil paintings including portraits, harbor scenes and landscapes.

In 1976, Brown suffered a severe stroke together with a myocardial infarction leaving him with a severe left-sided hemiparesis and hemineglect syndrome. Compared to his colleagues suffering from right-hemisphere damage, Brown was hit by the stroke in an even more devastating manner, since the paralyzed left arm was his 'drawing arm', and his doctors' prognoses as to future artistic work were pessimistic. His doctors were wrong: similar to Corinth and his wife Charlotte, Brown was helped to retrain his physical abilities and during his first steps back into arts by his wife Mary Louise, who was an artist as well. She was working with him day by day, so that he first started to draw and then to paint again. Emphasis was put on the effort to teach the 'good' right arm. Brown had to battle further a very dense left lower quadrantanopia; he would tend to leave the lower left portion of the canvas unpainted, started each painting session from the right side of a painting which resulted in canvasses heavily worked on to the right and thinly painted on the left. His portraits were disorganized with a marked distortion of facial structures, similar to Corinth's and Räderscheidt's (self-)portraits. Franz Brown comments on a stretching effect present from the upper right to the lower left, which decreased with time. The same effect can be seen in several of Corinth's portraits and self-portraits and in the series of Räderscheidt's self-portraits. A further source of frustration was the limited use of his previously dominant left hand, due to a severe reduction of

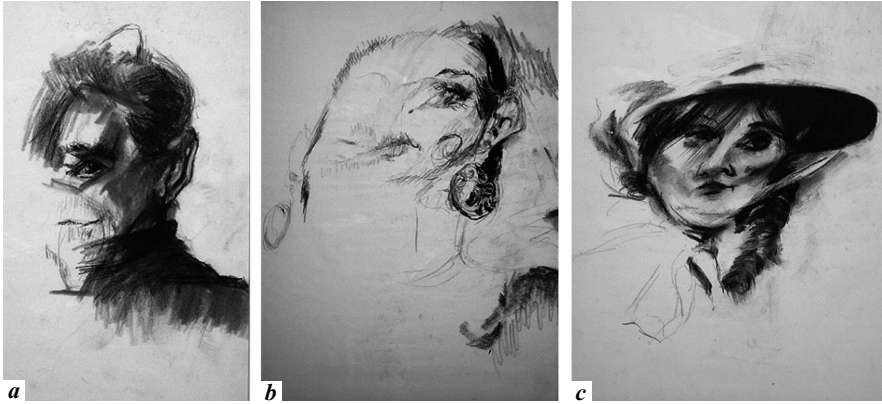

Fig. 4 a–c. Reynold Brown’s drawings and paintings produced in the period after his right-hemisphere stroke resemble strikingly the early poststroke artwork by Lovis Corinth and Anton Räderscheidt. His drawings show a severe left-sided hemineglect, which is improving throughout the following years (reproduced with permission of the Tejada-Brown family).

his tactile sense. In summary, according to his son, he was subsequently unable to do the highly representational work of his prestroke years, but ‘was nonetheless able to produce some powerful drawings and beautiful landscape paintings of Nebraska, where he settled in 1983 and remained until his death in 1991. Franz Brown states that his portraits ‘for some...carry a greater emotional impact than the more realistic work of his earlier years. His landscapes became looser and more painterly’ and he ‘seemed to see the world on different, more intense colours’.

In a striking similarity to the early poststroke artwork by Lovis Corinth, Brown’s poststroke drawings show a severe left-sided hemineglect, which is improving through the following years but never perfectly resolved as far as can be told (fig. 4).

(8) Tom Greenshields

Tom Greenshields (1915–1994), an accomplished and well-known painter and sculptor, was 75 years old, when he had a right-hemisphere stroke in August 1989 [Halligan and Marshall, 1997]. His symptoms included a mild sensorimotor hemisindrome on the left side, left lower quadrantanopia and left visual neglect. Already 8 years earlier, he had lost the use of his right painting arm in an accident. Therefore, he had learned to transfer his artistic skills to the left hand and continued to work as a painter and sculptor and to sell and exhibit his artwork. After his stroke, despite good physical recovery of his left arm and

hand function, he became frustrated facing poorly constructed and less elaborate drawings compared to prestroke creations. He concentrated on the right side of his drawings and sculptures and neglected the left parts. Moreover, his artwork showed distorted, exaggerated or deformed figures. On neuropsychological examination, visuospatial neglect was confirmed. Similar to Reynold Brown, he would ignore food on the left side of the plate. A photograph of a sculpture in the paper of Halligan and Marshall (fig. 1, bottom) shows a clay sculpture with intact facial proportions on the right side of the face and very incomplete modeling of the left parts of the face. Similar disturbances can be noticed in figure 2, a drawing of a sitting man with a missing left face, left shoulder and left parts of the chair. According to Halligan and Marshall, residual traces of neglect were still discernible until the death of the artist in 1994. This is the only case of a sculptor with a severe neglect described so far who reflected the difficulty of the right-hemisphere-damaged individual to detect and depict the third dimension.

(9) Unnamed Swiss Artist

Schnider et al. [1993] described the case of an unnamed Swiss artist who suffered a CT-documented large ischemic infarct in the right temporoparieto-occipital region. Poststroke drawings differed markedly from prestroke ones with changes reflecting both behavioral and mood disturbances. Their artist exhibited hemispacial neglect, hallucinations, hypervocalization (he would include much text in his early poststroke sketches), and a rapid cycling bipolar disorder. His drawings became simplified, more sketch-like, although the technical characteristics seemed similar to the premorbid artwork. Remarkably, the severity of neglect expressed in his drawings was highly variable and might change within hours.

(10) Artist with Right-Hemisphere Stroke

Vigouroux et al. [1990] published the case of an artist with right-hemisphere stroke. This unnamed 'well-known French painter' exhibiting a large variety of stroke risk factors presented with a severe left-sided sensorimotor hemisyndrome including a severe homonymous hemianopia to the left. Shortly after the stroke he experienced a severe depressive episode, apparently reflected in his drawings, which, according to the authors were of minor quality at that point although particularly expressive at the same time. This period was followed by a phase of rich pictorial production. Remarkably, these drawings and paintings showed no alteration of figural shape or volume, no change in style and unchanged artistic topics compared to the premorbid period but a variably severe hemineglect.

(11) 71-Year-Old Artist with Mild Left Neglect

Recently, Blanke et al. [2003] published the case of a 71-year-old artist with mild left neglect as the consequence of a right parietal hemorrhage. Drawings showed evidence of neglect to the left. Within these drawings, she used color minimally on the left whereas she colored the right side completely and evenly. Hence, she was able to produce the correct forms of images in the left visual hemifield but not the colors.

(12) Guglielmo Lusignoli

Guglielmo Lusignoli (born in 1920) was hit by a right-hemisphere stroke in 1987 at the zenith of his creativity and artistic production [Mazzucchi et al., 1994]. He suffered from hemineglect and left-sided paresis; however, he resumed his work and was enormously productive after the stroke.

(13) Kurt Schwitters

As far as can be told from his biography [Orchard et al., 1998], the famous German Dada artist Kurt Schwitters (1887–1948) suffered a right-hemisphere stroke in 1944 with a subsequent paresis of his left arm. A second stroke (presumably a hemorrhage) occurred in February 1946. In December 1945 he writes: ‘I am [now] painting smaller formats and do some very small modelling, pocket format. My sculptures are a new experience for me; they are my best works now’ [Orchard et al., 1998]. Further evidence for any alterations in artistic expression is scarce.

Conclusions

This series of 13 visual arts professionals with right-hemisphere stroke illustrates the consequences of stroke for their artistic creation. The painters reported had a mean age of 66 years at stroke onset and survived their first stroke for more than 6 years.

(1) Not surprisingly, the immediate reaction to the devastating and unexpected stroke ‘attack’ is very often a period of depression and despair. A stroke may lead to sometimes very severe episodes of depression and even to suicide attempts. Valuable introspective comments on their disease can be found in the reports of Lovis Corinth [Bänzner and Hennerici, pp. 30–43] and Wolfgang Aichinger-Kassek [1996].

(2) The stroke influences the painting in the vast majority of artists to a relevant degree. Whereas in some cases the stroke ended the artistic career (Fellini) [Dieguez et al., pp. 44–74], the majority of the painters reported resumed artistic production although they had to overcome various degrees of disability.

(3) Reynold Brown, a previously left-handed artist, suffered a right-hemisphere stroke and had to learn to use his previously nondominant right hand. His artwork was further altered by severe visual disturbances.

(4) Visuospatial neglect is common in right-hemisphere stroke. Noticeable degrees of neglect can be deferred from the poststroke artwork of virtually all of the right-hemisphere patient-artists. This severe problem for the visual artist is often compensated in paintings of the wider scenery of landscapes and large figural compositions, but is commonly detectable in self-portraits due to the necessity of strong fixation in the center of the visual field.

(5) The finding of facial distortion in at least 6 of the right-hemisphere patients hints at the representation of both facial recognition and spatial organization in the right hemisphere. Also the striking loss of self-resemblance in the self-portraits of Corinth, Dix, and Räderscheidt points to a certain degree of prosopagnosia in these right-hemisphere stroke victims.

(6) Spatial organization is disturbed in several of the right-hemisphere painters with disturbances of perspective or of third dimension in sculptural creation. In the poststroke artwork by Corinth, Räderscheidt, Dix, Greenshields and Brown, anatomical exactitude is altered, details are misplaced.

(7) Hallucinatory episodes, delusions, and dream-like optical sensations can be found in the case histories of several of the right-hemisphere stroke painters such as Räderscheidt, Corinth, Aichinger-Kassek, and Schnider's case.

References

- Aichinger-Kassek W: Neurological Folios. Kranj, Gorenjski Tisk, 1997.
- Blanke O, Ortigue S, Landis T: Colour neglect in an artist. *Lancet* 2003;361:264.
- Butter CM: Anton Raederscheidt's distorted self-portraits and their significance for understanding balance in art. *J Hist Neurosci* 2004;13:66–78.
- Cantagallo A, Della Sala S: Preserved insight in an artist with extrapersonal spatial neglect. *Cortex* 1998;34:163–189.
- Chatterjee A: The neuropsychology of visual artistic production. *Neuropsychologia* 2004;42:1568–1583.
- Gardner H: The pathology of art; in *The Shattered Mind*. London, Routledge & Kegan Paul, 1977, pp 291–349.
- Halligan PW, Marshall JC: The art of visual neglect. *Lancet* 1997;350:139–140.
- Herzog G: Anton Räderscheidt. Cologne, DuMont, 1991.
- Jung R: Neuropsychologie und Neurophysiologie des Kontur- und Formsehens in Zeichnung und Malerei; in Wieck HH (ed): *Psychopathologie musischer Gestaltungen*. Stuttgart, Schattauer, 1974, pp 29–88.
- Kinkel H: Einleitung; in Karsch F (ed): *Otto Dix, Das graphische Werk*. Hannover, Fackelträger, 1970.
- Mazucchi A, Pesci G, Trento D: *Cervello e pittura: Effetti delle lesioni cerebrali sul linguaggio pittorico*. Rome, Fratelli Palombi, 1994.
- Orchard K, Schulz I, Brogden J: *Kurt Schwitters: Werke und Dokumente. Verzeichnis der Bestände im Sprengel Museum Hannover*. Hannover, Sprengel Museum, 1998.
- Richter H: *Anton Räderscheidt*. Recklinghausen, Bongers, 1972.

- Schnider A, Regard M, Benson DF, Landis T: Effects of a right hemisphere stroke on an artist's performance. *Neuropsychiatry Neuropsychol Behav Neurol* 1993;6:249–255.
- Schubert D: *Otto Dix*. Reinbek, Rowohlt, 1980.
- Vigouroux RA, Bonnefoi B, Khalil R: Réalisations picturales chez un artiste peintre présentant une hémiparésie gauche. *Rev Neurol (Paris)* 1990;146:665–670.

Hansjörg Bänzner, MD, PhD
Department of Neurology, University of Heidelberg
Universitätsklinikum Mannheim, Theodor Kutzer Ufer 1-3
DE-68135 Mannheim (Germany)
Tel. +49 621 383 3555, Fax +49 621 383 3807, E-Mail baezner@neuro.ma.uni-heidelberg.de